

## OLGU SUNUMU

## CASE REPORT

## A metastatic seminoma in a dog ▶

İbrahim DEMİRKAN<sup>1\*</sup>, Hayati YÜKSEL<sup>2</sup>,  
Musa KORKMAZ<sup>1</sup>, Aysun ÇEVİK-DEMİRKAN<sup>3</sup>

## SUMMARY

A 12 year-old, male, mixed breed dog was referred to our clinic suffering from enlarged testicle. The testicle had become extensively larger within last 6 months. The dog was emaciated and showed a small ulcerated lesion on the right scrotum. The testicular area was quite sensitive to touch especially in milieu of enlarged testicle. Abdominal and thoracic radiography was taken. Because of the nature of the enlarged testicle it was decided to perform bilateral orchiectomy (included sound testicle). A cauliflower like growth was observed within preputium adhered to the midway of the shaft of the penis. Therefore partial amputation of penis including the growth was also achieved. To observe whether the tumor metastasized to the nearest lymph node, right superficial inguinal lymph node was removed for histopathological examination. The mass was 14x9 cm in size and weighed 550 g. The case was determined to be a metastatic seminoma in histopathological evaluation. X-ray images showed that the tumor metastasized to the lungs. Two weeks postoperatively Cisplatin chemotherapy protocol was initiated at a dosage of 60 mg/m<sup>2</sup> (diluted in 370 ml of saline) intravenously. After 1 month the dog was brighter. Appetite and activity level of the dog increased. No surgical complication or medication was observed at the final control (at the 18th month of postsurgery).

•••

## Bir köpekte metastazik seminoma

## ÖZET

Oniki yaşında erkek, melez bir köpek testislerinde büyümeye bağlı ağrıdan dolayı kliniğimize getirildi. Testisin son 6 ayda aşırı büyüdüğü bildirildi. Köpeğin aşırı zayıflamış ve sağ skrotum üzerinde küçük ülseratif lezyonların bulunduğu gözlemlendi. Testiste büyümenin olduğu bölge dokunmaya oldukça duyarlıydı. Abdominal ve torakal radyografi çekildi. Testisin yapı olarak çok büyüdüğünden bilateral orşiektomi'ye (sağlam testisle birlikte) karar verildi. Penisin ortasına kadar uzanan prepusyuma yapışmış karnıbahar benzeri üremeler görüldü. Bu yüzden büyümelerinde içermek kaydıyla penis kısmi penis amputasyonu yapıldı. En yakın lenf nodulüne metastaz yapıp yapmadığını görmek için sağ *ln inguinalis superficialis dextra* histopatolojik inceleme amacıyla uzaklaştırıldı. Kitle 14x9 cm boyutunda ve 550 g ağırlığındaydı. Histopatolojik muayenede olgunun metastazik seminoma olduğu tespit edildi. Radyografik görüntü tümörün akciğerlere metastaz yaptığını gösterdi. 60 mg/m<sup>2</sup> (370 ml serum fizyolojikte dilüe edilerek) dozunda intravenöz yolla Cisplatin kemoterapi protokolü başlatıldı. Bir ay sonraki kontrolde köpek daha canlıydı. İştah ve aktivite artmıştı. Son kontrolde (postoperatif 18. ay) herhangi bir cerrahi ve ilaçla sağaltımıyla ilgili komplikasyon gözlenmedi.

## Key Words

Seminoma  
Surgery  
Chemotherapy  
Dog

## Anahtar Kelimeler

Seminoma  
Cerrahi  
Kemoterapi  
Köpek

Departments of Surgery<sup>1</sup>,  
Pathology<sup>2</sup> and Anatomy<sup>3</sup>  
Faculty of Veterinary Medicine  
Afyon Kocatepe University  
03200- Afyonkarahisar  
TURKEY

## \* Corresponding author

Tel: +90 272 214 9309  
Fax: +90 272 214 9055  
Email: idemirkan@aku.edu.tr

▶ A part of this work was presented at the XI. Ulusal Veteriner Cerrahi Kongresi, Aydın, TURKEY, as a poster

## INTRODUCTION

Testicular tumors and Leydig cell hyperplasia are common findings in aged dogs unlike in other domestic animals.<sup>1</sup> The prevalence varies from 0,07 to 4,60 % in male dogs<sup>2,3</sup> and especially in older dogs the prevalence can be as high as 60 %.<sup>4</sup> In men, however, testicular tumors occur most often in adults older than 40 years of age<sup>5</sup>. The three main types of testicular neoplasms in dogs are Sertoli cell tumors, seminomas and Leydig cell tumors, and these tumors occur at about equal frequencies.<sup>6</sup> In dogs, Sertoli cell tumors, seminomas and interstitial cell tumors account for most of the testicular neoplasms.<sup>7,8</sup> Other canine testicular tumors such as gonadoblastomas, schwannomas and leiomyomas are rarely reported.<sup>9-11</sup> Sertoli cell tumors, seminomas and Leydig cell tumors are seldom lethal and can cause feminization of the dog, which in severe cases can lead to a fatal bone marrow depression. Feminization is caused by hyperestrogenism and is mostly associated with Sertoli cell tumors but Leydig cell tumors and seminomas have also been associated with this syndrome. When feminization occurs in dogs with a seminoma, it is presumed that a co-existing Sertoli or Leydig cell tumor is responsible for the hyperestrogenism.<sup>6</sup>

Cryptorchidism is an important risk factor for the development of testicular tumors, causing a 26-fold increase in the risk for Sertoli cell tumors and a 15-fold increase for seminomas.<sup>12</sup> Although Sertoli cell tumors and seminomas are considered to be potentially malignant, they seldom metastasize in the dog, whereas seminomas in men are highly malignant.<sup>13</sup> Both Sertoli cell tumors and Leydig cell tumors can cause increased estrogen production leading to signs of feminization and alopecia, but seminomas were not endocrinologically active.<sup>1</sup>

In dogs, seminomas arising from the retained abdominal or inguinal testicles, without scrotal involvement, are usually benign, although a malignant one with extensive metastasis has been reported. Seminoma arising from extragonadal germ cells has not been identified in dogs.<sup>14</sup>

The seminoma of the testis develops from germ cells before somatic differentiation.<sup>15</sup> They arise from cells of the spermatogenic series, presumably from basal spermatogonia.<sup>16</sup>

This paper discusses the surgical intervention, histopathology and postoperative chemotherapy of a metastasized seminoma in a dog.

## CASE HISTORY

A 12 years old, male dog was referred to the Department of Surgery, Afyon Kocatepe University Faculty of Veterinary Medicine due to testicular enlargement. According to the owner, anorexia and increased live body weight loss of 5 kg over the last month was noted. The dog's testicle became larger than the normal size within the last 6 months. Dog was reluctant to do exercise even owner's commands.

On physical examination, the dog was emaciated and showed a small ulcerated lesion on the scrotal skin in addition to an enlarged right testicle (Figure 1). Respiration, heart rate, urination and reflexes were in normal range. However the testicular area was quite sensitive to touch especially in the milieu of enlarged testicle.

Because of the nature of the enlarged testicle we decided to carry out bilateral orchidectomy (including sound testicle). Following 12 hour fasting animal was premedicated with 0.045 mg/kg of atropine sulphate and sedated with intramuscular administration of xylazine HCl (Rompun %2, Bayer, İstanbul) at a dose of 2 mg/kg. Following the sedation, 10 mg/kg Ketamine HCl was intravenously given. Fluid administration (Lactated Ringer's solution) was provided before, during and after the surgery. To this end, an aseptic surgery was performed. A circular skin incision was made at the base of the scrotum. *Canalis inguinalis* was carefully exposed. Double clamps was applied to the *ductus deferences* and the *plexus panpiniformes*. The testicles were transected between the clamps. A cauliflower-like growth was also observed within the *preputium* adhered to the midway of the shaft of the penis. Therefore partial amputation of penis including the growth was achieved accordingly.

To observe whether the tumor metastasized to the nearest lymph node, the right superficial inguinal lymph node was removed for histopathological examination. Tissues (testicle and lymph node) were fixed in 10% formalin solution and embedded in paraffin. Five micron sections were stained with hematoxyline and eosin (H&E) and examined under a light microscope. An Elizabethian collar was placed on the neck of the dog for 10 days during the wound healing. Metronidazole 15 mg/kg live body weight, per os, twice a day for 10 days and cephalixin, 30 mg/kg live body weight for

14 days, postoperatively, were given to accomplish the required antibiotic level. The dog recovered from the anaesthesia uneventfully. After 14 days of operation (at the end of the antibiotherapy) cisplatin (Cisplatin, Med İlaç, Ankara, Turkey) chemotherapy protocol was initiated at a dosage of 60 mg/m<sup>2</sup> (diluted in 370 ml of saline) intravenously. It was repeated twice with 3 week-intervals.

After 8 weeks of the operation, the dog was brighter and the owner reported increased appetite and activity level of the dog.

The quality of life of the dog was evaluated before and after the operation. Follow up period was 14 months.

In macroscopic examination the mass was 14x9 cm in size and weighed 550 g (Figure 2). Cross sectioning showed exuberant lobular architecture in grey-white colour and patchy haemorrhage (Figure 3). There were necrotic areas.

In histopathology, oval and polyhyal anaplastic tumor cells in various size with sharp edges were observed in place of disappeared *tubulus seminiferus*. These cells were giant cells with basophilic cytoplasm and hyperchromatic nucleus. In nucleus of some cells there was prominent one or more nucleolus. Mitotic figures and few number of giant cells were noted in the areas where anaplastic cells were widespread (Figure 4). Tumor cells infiltrated into *tunica albuginea* in some zones and in the right superficial inguinal lymph node were seen.

Abdominal and thoracic radiography was taken on the arrival, 2-week postsurgically (at the start of chemotherapy), at the 5th week and it was repeated every month until the 18th month for the evidence of recurrence.

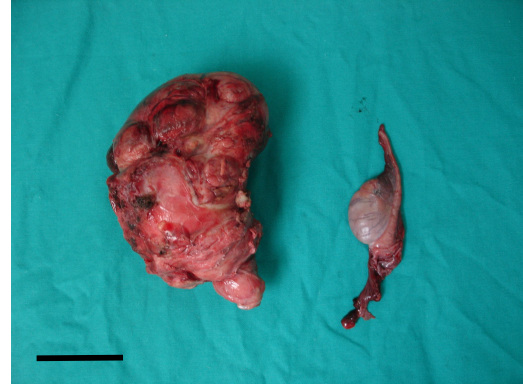


Figure 2. Removed neoplastic and normal testicles (Bar: 5 cm)  
Şekil 2. Uzaklaştırılan neoplastik ve normal testis (Çubuk: 5 cm)

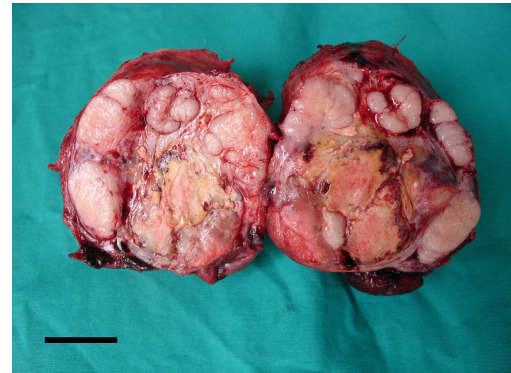


Figure 3. Cross-section of neoplastic testicular tissue (Bar: 3 cm)  
Şekil 3. Neoplastik testis dokusunun enine kesiti (Çubuk 3 cm)

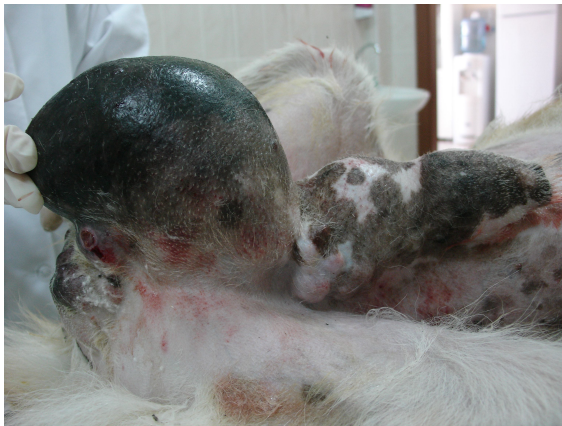

Figure 1. Preoperative appearance of scrotum  
Şekil 1. Skrotumun operasyon öncesi görünümü

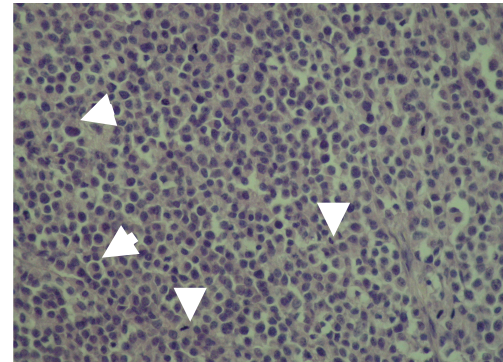
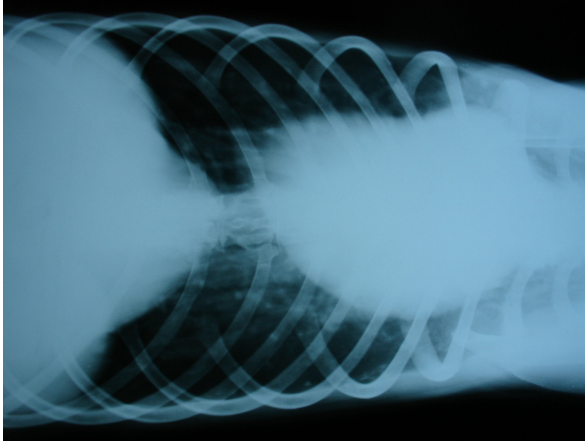


Figure 4. Histopathologic staining of testicular tissue (arrows show giant cells whereas arrow heads show mitotic figures, x40)  
Şekil 4. Testis dokusunun histopatolojik boyaması (oklar dev hücreleri okbaşı ise mitotik figürleri göstermektedir, x40)



**Figure 5.** X-ray image of thorax of the dog (note: intensive foci in the lungs)  
**Şekil 5.** Köpeğin toraks röntgen görüntüsü (not: akciğerlerde yoğun odaklar)

## DISCUSSION

The age of the dog was 12 year-old in the current case. Similarly, the average age for seminoma was 10 year-old in the literature.<sup>18</sup> Behavioral changes were subtle. Gross characteristics of the tumors in this study were very similar to those described previously.<sup>19-21</sup>

Testicular seminomas are typically focal to diffuse and flaccid to semi-firm with a homogenous glistening gray/white appearance on cut surface.<sup>17</sup> Similar to Sertoli cell tumors, they are often lobulated and compress the surrounding testicular tissue.<sup>15</sup> Occasional foci of necrosis and hemorrhage may be present<sup>15</sup> similar to our findings. The texture of seminomas helps differentiate them from Sertoli cell tumors, which are usually more firm.<sup>17</sup> Seminomas have a unique histological appearance, and are sub-classified as intratubular and diffuse/solid. The diffuse subtype is a continued progression of the intratubular type to a more infiltrative pattern, and no proven correlation exists between subtype and metastatic behavior.<sup>15</sup> Tumor cells are highly characteristic and appear as very large, polyhedral cells with sharp borders, vesicular nuclei, prominent nucleoli, and scant basophilic to amphophilic cytoplasm.<sup>17</sup> In many seminomas as observed in our case, multinucleate cells are common, and mitotic figures are typically numerous and bizarre.<sup>15,17</sup> Tumors may be subdivided by loose stroma infiltrated by focal aggregates of lymphocytes.<sup>15,17</sup> Individual cell necrosis with scattered

histiocytes may produce a classic "starry-sky" appearance, which is characteristic for but not diagnostic of diffuse testicular seminomas.

The metastatic cells resemble those of the primary tumor but, in general, form fewer tubules. Neoplastic cells tend to infiltrate tissues outside of the tubules and invade the tunica, epididymis, local lymphatics, and veins.<sup>19</sup> The cells are irregularly circular rather than spindle-shaped and exhibit a finer vacuolation; as well, the incidence of mitotic figures is often increased. The presence of metastases confirms a malignant tumor, and the best clinical indication of metastases is the recurrence of the feminization syndrome after removal of the primary tumor.<sup>22</sup> The dog showed feminization syndrome until the last control (the 18th month of postsurgery).

Seminomas are, however, associated with cryptorchidism and produce feminizing changes similar.<sup>23</sup> But this was not the case in our case. They also tend to metastasize more frequently than other testicular tumors.<sup>24</sup>

Generally, the routes of metastatic spread of testicular tumors are via lymphatics to the inguinal and sublumbar lymph nodes.<sup>25,26</sup> Metastases may also be found in mesenteric and periaortic lymph nodes, liver, lungs, kidneys, spleen, and adrenal glands<sup>19</sup> as in our case.

Bilateral orchiectomy is the treatment of choice in cases of malign testicular tumors, especially if the affected dog is cryptorchid regardless of the location of the tumors. Both bilaterally retained testes should be removed because of the increased risk of neoplasia. Unilaterally cryptorchid animals should also undergo the bilateral procedure for removal of the tumor and to prevent dissemination of the cryptorchid trait in the population.<sup>27</sup>

It was concluded that surgical removal of the seminoma and administration of cisplatin may be a beneficial approach for the canine testicular cancer patients ■

## REFERENCES

1. Peters MA, de Jong FH, Teerds KJ, de Rooij DG, Dieleman SJ, van Sluijs FJ (2000) Ageing, testicular tumours and the pituitary-testis axis in dogs. *J Endocrinol*, 166: 153-161.
2. Peters MA, Teerds KJ, van der Gaag I, de Rooij DG, van Sluijs FJ (2001) Use of antibodies against LH receptor, 3beta-hydroxysteroid dehydrogenase and vimentin to characterize different types of testicular tumour in dogs. *Reproduction* 121: 287-296.
3. Weller RE, Dagle GE, Buschbom RL, Park JF (1995) Examination of testicular tumours in the beagle dog exposed to inhaled plutonium. *Int J Radiat Biol*, Jul;68(1):63-70.
4. Mosier JE (1989) Effect of aging on body systems of the dog. *Vet Clin North Am*, 19:1-12.
5. Looijenga LH, Olic RA, van der Gaag I, van Sluijs FJ, Matoska J, Ploemzaaijer J, Kneple C, Oosterhuis JW (1994) Seminomas of the canine testis – counterpart of spermatocytic seminoma of men? *Lab Invest*, 71: 490-496.
6. Nielsen SW, Kennedy PC (1990) Tumors of the genital systems. In: *Tumors in Domestic Animals*, JE Moulton (ed). Berkeley: University of California Press. pp 479-517.
7. Cihak RW, Roen DR, Klaassen J (1986) Malignant mesothelioma of the tunica vaginalis in a dog. *J Comp Pathol* 96: 459-462.
8. Taniyama H, Hirayama K, Nakada K, Numagami K, Yaosaka N, Kagawa Y, Izumisawa Y, Nakade T, Tanaka Y, Watanabe G, Taya K (2001) Immunohistochemical detection of inhibin-alpha, -betaB, and -betaA chains and 3betahydroxysteroid dehydrogenase in canine testicular tumors and normal testes. *Vet Pathol*, 38:661-666.
9. Patnaik AK, Liu SK (1975) Leiomyoma of the tunica vaginalis in a dog. *Cornell Vet*, 65:228-231.
10. Rothwell TL, Papamitriou JM, Xu FN, Middleton DJ (1986) Schwannoma in the testis of a dog. *Vet Pathol*, 23:629-631.
11. Turk JR, Turk MA, Gallina AM (1981) A canine testicular tumor resembling gonadoblastoma. *Vet Pathol*, 18:201-207.
12. Hayes HM, Wilson GP, Pendergrass TW, Cox VS (1985) Canine cryptorchidism and subsequent testicular neoplasia: case-control study with epidemiologic update. *Teratology*, 32 51-56.
13. Swerdlow AJ (1993) The epidemiology of testicular cancer. *Eur Urol*, 23 35-38.
14. Wang F, Liang SL, Chin SC (2001) A primary retroperitoneal seminoma invading the kindeys of a cryptorchoid dog, *Exp Anim*, 50:341-344.
15. Kennedy PC, Cullen JM, Edwards JF, Goldschmidt MH, Larsen S, Munson L, Nielson S (1998) *Histological classification of tumors of the genital system of domestic animals*. Washington DC, Armed Forces Institute of Pathology, pp. 15-20.
16. Ladd PW (1993) The male genital system. In: *Pathology of Domestic Animals*. Jubb KVF, Kennedy PC, and Palmer N (eds) 4<sup>th</sup> ed. San Diego, Academic Press, pp. 504-511.
17. Meuten DJ (2002) *Tumors in Domestic Animals*, 4<sup>th</sup> ed. Ames, Iowa State Press, pp. 561-567.
18. Post K, Kilborn SH (1987) Canine sertoli cell tumor: A medical records search and literature review. *Can Vet J*, 28:427-430.
19. Moulton JE (1978) Tumors of the genital system. In: *Tumors in Domestic Animals*, 2nd ed, Berkeley, University of California Press, pp. 309-315.
20. Pulley LT (1979) Sertoli cell tumor. *Vet Clin North Am*, 9: 145-150.
21. Brodey RS, Martin JE (1958) Sertoli cell neoplasms in the dog. *J Am Vet Med Assoc*, 133: 249-257.
22. Pulley LT (1979) Sertoli cell tumor. *Vet Clin North Am*, 9: 145-150.
23. Lipowitz AJ, Schwartz A, Wilson GP, Ebert JW (1973) Testicular neoplasms and concomitant clinical changes in the dog. *J Am Vet Med Assoc*, 163: 1364-1368.
24. Broadhurst JJ (1974) Neoplasm of the reproductive system. In: *Current Veterinary Therapy V*. Philadelphia, WB Saunders Co., pp. 928-937.
25. MacLachlan NJ, Kennedy PC (2002) Tumors of the genital systems. In: *Tumors in Domestic Animals*. Meuten DJ. (Ed). 4<sup>th</sup> ed. Iowa State Press, USA, pp. 547-575.
26. Weaver AD (1983) Survey with follow-up of 67 dogs with testicular Sertoli cell tumors. *Vet Rec*, 113: 105-107.
27. Wallace LU (1980) Canine cryptorchidism. In: *Current Veterinary Therapy VII*. Philadelphia: W.B. Saunders Co. pp. 1244-1246.

