

Eye Injuries in Cats with Head Trauma

Kurtuluş PARLAK^{1*}, Eyüp Tolga AKYOL², Nuriza ZAMİRBEKOVA¹, Songül ARAS¹, Saniye KAYACIK¹, Ümmü Gülsüm Fatma BORAN ÇAYIRLI¹, Yasemin TANIRLI¹, Kadir SULU¹, Fahrettin ALKAN¹

¹ Department of Surgery, Faculty of Veterinary Medicine, University of Selçuk, 42130, Konya, Turkey.

² Department of Surgery, Faculty of Veterinary Medicine, Balıkesir University, 10145, Balıkesir, Turkey.

ABSTRACT

Head trauma may lead to damage of soft tissue and bones of skull by an external force. The modified Glasgow coma scale (mGCS) is used to evaluate the prognosis and classify the neurological status of cats and dogs with head trauma. The aim of this study is determine the ophtalmic pathologies and the incidence of these pathologies as a result of head trauma in cats. In addition, any possible correlation between intraocular pressure (IOP) and mGCS will be investigated in traumatized cats. The animal material of the study consisted of 18 cats with acute head trauma. The animals were properly restricted so that mGCS scores were recorded. Systematic eye examination was performed as far as the clinical condition of the patient allowed during the clinical examination and treatment of the traumatized cats. Proptosis was observed in 4 cats (22.22%) as unilaterally in 3 cats and bilaterally in 1 cat. Subconjunctival hemorrhage was observed in 7 cats (38.88%) as bilaterally in 2 cats and unilaterally in 5 cats. Unilateral hyphema was observed in 2 cats (11.11%). Three cats had anisocoria (16.66%), 2 cats had unilateral nystagmus (11.11%), and 1 cat had unilateral Horner's syndrome (5.55%). In cats with glaucoma the median mGCS was 8 (score 4-15), while non-glaucoma the median mGCS was 9 (score 6-14). However, no statistical correlation was found between mGCS and glaucoma ($p>0.05$). The results of this study indicate that glaucoma, subconjunctival hemorrhage and proptosis are the most common pathologies in cats with head trauma and these pathologies should not be ignored during the intervention of the head trauma patients. In addition, it is thought that irreversible loss of vision can be prevented by frequently repeated IOP measurements, regardless of the mGCS score, in cases with head trauma.

Key Words: Cat, head trauma, eye injury, mGCS, trauma.

Kafa Travmalı Kedilerde Göz Yaralanmaları

ÖZ

Kafa travması, harici bir kuvvetle yumuşak doku ve kafatası kemiklerinin hasar görmesine neden olabilir. Modifiye Glasgow koma skalası (mGCS), kafa travmalı kedi ve köpeklerin prognozunu değerlendirmek ve nörolojik durumlarını sınıflandırmak için kullanılır. Bu çalışmanın amacı, kedilerde kafa travması sonucu oluşan oftalmik patolojileri ve bu patolojilerin görülme sıklığını belirlemektir. Ayrıca travma geçirmiş kedilerde göz içi basıncı (GİB) ile mGCS arasındaki olası ilişki araştırılacaktır. Araştırmanın hayvan materyalini akut kafa travmalı 18 kedi oluşturmuştur. Hayvanlar uygun şekilde kontrol altına alınıp, mGCS skorları kaydedildi. Travma geçiren kedilerin klinik muayenesi ve tedavisi sırasında hastanın klinik durumunun izin verdiği ölçüde sistematik göz muayenesi yapıldı. Proptozis 4 kedide (%22.22); 3 kedide unilateral, 1 kedide bilateral olarak gözlemlendi. Subkonjonktival kanama 7 kedide (%38.88); 2 kedide bilateral, 5 kedide tek taraflı olarak gözlemlendi. 2 kedide (%11.11) tek taraflı hifema görüldü. Üç kedide anizokori (%16.66), 2 kedide unilateral nistagmus (%11.11) ve 1 kedide tek taraflı Horner sendromu (%5.55) görüldü. Glukomlu kedilerde medyan mGCS 8 (skor 4-15), glukom olmayan kedilerde medyan mGCS 9 (skor 6-14) olarak kaydedildi. Ancak mGCS ile glukom arasında istatistiksel bir ilişki bulunamadı ($p>0.05$). Kafa travmalı kedilerde glukom, subkonjonktival kanama ve proptozis patolojilerinin en sık görülen patolojiler olduğu ve kafa travmalı hastaların müdahalesinde bu patolojilerin göz ardı edilmemesi gerektiği sonucuna varıldı. Ayrıca kafa travmalı olgularda mGCS skoru ne olursa olsun göz içi basınç ölçümlerinin sık sık tekrarlanmasıyla geri dönüşü olmayan görme kaybının önlenilebileceği düşünülmektedir.

Anahtar Kelimeler: Göz yaralanması, kafa travması, kedi, mGCS, travma.

To cite this article: Parlak K, Akýol E.T, Zamirbekova N, Aras S, Kayacık S, Boran Çayırılı Ü.G.F, Tanırlı Y, Sulu K, Alkan F. Eye Injuries in Cats with Head Trauma. Kocatepe Vet J. (2021);14(4) 482-491

Submission: 12.10.2021 Accepted: 29.11.2021 Published Online: 06.12.2021

ORCID ID; KP: 0000-0002-8656-037X, ETA: 0000-0002-9775-7557, NZ: 0000-0003-4465-5511, SA: 0000-0003-4922-7663, SK: 0000-0001-5231-4798, ÜGFBC: 0000-0001-9131-0917, YT: 0000-0001-6653-9891, KS: 0000-0002-7246-8185, FA: 0000-0001-9637-1903

*Corresponding author e-mail: kparlak@selcuk.edu.tr

INTRODUCTION

Head trauma may lead to damage of soft tissue (including brain, skin and eyes) and bones of skull by an external force. Rapid diagnosis and response to the trauma patient is required to ensure the best prognosis (Kuo et al. 2018). Approximately 50% of cats and dogs are exposed to head trauma due to more frequently high-energy blunt traumas such as motor vehicle accidents and contusion injuries. Falls from a height, gunshot wounds, intentional/unintentional attacks from other animals and humans also are other common causes of trauma (Platt 2008, Dewey and Fletcher 2015). Traumatic pathologies tend to be encountered in more than one body system and often including the head region in feline trauma patient with a small size of body. Extremity injuries are the most common pathologies in traumatized cats, followed by head injuries (Rochlitz 2004).

The modified Glasgow coma scale (mGCS) is used to evaluate the prognosis and classify the neurological status of cats and dogs with head trauma. This scale; divided into three neurologic examination categories that assess level of consciousness, motor activity, and brainstem reflexes. Each category is scored from 1 to 6 with 1 indicate to more severe dysfunction. The obtained scores from each category added together to establish coma score. The patient's condition is classified as grave (3-8), guarded (9-14), or good (15-18) according to the established coma score. High scores tend to with the best prognosis, while low scores associated with more than 50% mortality rate over the 1st 72 hours. This scoring system provides information about patient assessment, prediction of treatment response, evaluation of therapeutic options, and the prognosis (Platt et al. 2001, Platt and Olby 2004, Dewey and Fletcher 2015).

The first ophthalmic pathology associated with forebrain damage as a result of trauma in cats and dogs is myosis of the pupils. Due to the progression of forebrain and/or brainstem damage, the pupils are observed as mydriatic and response to light stimuli. These clinical signs could be associated with brain herniation accompanied by altered consciousness and cardiorespiratory patterns (Platt 2008, Sande and West 2010, Opperman 2014, Dewey and Fletcher 2015). Glaucoma represents a diverse group of diseases. In all species, it results in vision loss caused by characteristic optic nerve and retinal pathology. Glaucoma is therefore generally considered a neurodegenerative disease. The most important and only risk factor for the development of glaucoma is increased intraocular pressure (IOP) (McLellan and Miller 2011). The TonoVet® rebound tonometer is more accurate, especially at IOP >30 mmHg; does not require topical anesthetic, well tolerated by cats. Normal IOP is 20.74 ± 0.5 mmHg with the TonoVet® rebound tonometer in cats (Rusanen et al. 2010).

Secondary glaucomas, constituting for 95-98% of glaucoma cases in cats, are associated with altered aqueous humor dynamics due to uveitis, neoplasia, trauma, and intraocular hemorrhage (Blocker and van der Woerd 2001). Underlying Depending on the pathogenesis, they may be unilateral or less frequently bilateral in presentation and are most common in adult cats (McLellan and Miller 2011).

The aim of this study is determine the ophthalmic pathologies and the incidence of these pathologies as a result of head trauma in cats. In addition, any possible correlation between IOP and mGCS will be investigated in traumatized cats.

MATERIALS and METHODS

Animals

The animal material of the study consisted of 18 cats (different breeds, ages and genders) presented to Selcuk University, Faculty of Veterinary Medicine, Surgery Clinic and Emergency Unit with acute head trauma. Care was taken to ensure that any drug therapy such as fluid-electrolyte (mannitol, diuretic, etc.), analgesics and corticosteroids were not used in the cats included in the study. Cats with head trauma within 24 hours selected for the study inclusion.

Clinical Examination

Cats with head trauma evaluated primarily for life-threatening abnormalities. As in every trauma patient, evaluation of ABC (airway, breathing and circulation) is very critical for emergency interventions. However, the determination of hypovolemia and hypoxemia also was performed (Sande and West 2010). After the all of these evaluations, an IV catheter was placed in the cephalic vein of the forelimb and routine clinical examinations were performed with mGCS at the same time (Platt and Olby 2004, Dewey and Fletcher 2015). The animal was properly restricted so that mGCS scores were recorded. Each animal was graded as grave (3-8), guarded (9-14) or good (15-18), with adding each score in the three categories including motor and brainstem reflexes and level of consciousness. In addition, systemic hematological examinations (blood gas analysis (GEM Premier 3000, USA) and hemogram (MS4e, France)) were performed in the Central Laboratory, Faculty of Veterinary Medicine, Selcuk University.

Treatment Protocol

In order to maximize venous drainage from the brain and minimize the increase in intracranial pressure (ICP), the traumatized cat positioned with head elevated 30° angle of body level. Also, compression of the jugular vein was avoided since this leads to increase in ICP. Initially, supplemental oxygen (50-100 ml/kg/min) administered via face-mask to the cats over 15 minutes and also care was taken to ensure that aggressive hyperventilation used for short

periods. The mask was changed periodically to prevent rebreathing of carbon dioxide. This flow-by oxygen was delivered in a stress-free manner to prevent ICP increase due to fluttering. Fluid and electrolyte administration were performed considering clinical and hematological evaluations and mGCS results. Depending on severity of the clinical condition of the cat, one-third of the shock dose (15-20 ml/kg/hour) 0.9% sodium chloride (NaCl) or lactated Ringer's solutions were administered by IV infusion over 15 to 30 minutes. An osmotic diuretic, mannitol (1 g/kg, IV, over 15-30 minutes) was administered to suspected cats with increase ICP. Vaso-active agents such as dopamine (2-10 mcg/kg/min, IV infusion) were used for arterial blood pressure support in the presence of arterial hypotension despite fluid resuscitation. Clinically stabilized cats as result of treatments were prepared for tomographic examination. Also, in case of post-traumatic epileptic disorder, levatiracetam (20 mg/kg, PO, q8) and phenobarbital (7.5 mg, IM, q12) were used (Platt 2008, Sande and West 2010, Dewey and Fletcher 2015).

Computed Tomographic (CT) Examination

Cats with acute head trauma were included in CT examination according to their clinical status and in severe trauma cases, examination was postponed. Examination was performed after the administration of butorphanol (0.1 mg/kg, IV, Butomidor®, Interhas) and medetomidine HCl (40-80 mcg/kg, IM, Domitor®, Zoetis), which are routinely used in trauma patients for pain management and restriction. In cases of sedative drugs were not sufficient, anesthesia was provided with propofol (4-6 mg/kg, IV, Propofol-PF, Polifarma) according to the clinical condition of the animal. For tomographic examination (Asteion, Toshiba Medical Systems Corporation, Japan), 120 kV, 100 mA and 2 mm slice thickness values were selected and performed in helical cranial scanning mode.

Eye Examination

Systematic eye examination was performed as far as the clinical condition of the patient allowed during the clinical examination and treatment of the traumatized cats. Pupillary light reflexes and oculocephalic reflexes were noted with direct inspection. Schirmer tear test and florescein staining were performed in the presence of corneal lesion. Cornea, iris, lens and fundus were examined with a direct ophthalmoscope (Hasvet, Turkey). Intraocular pressure (IOP) measurement (Icare Tonovet Plus, Finland) was performed. In cases of the fundus was suspected, examination was performed with the retinal camera (ClearView® 2, United Kingdom). Ultrasonographic (Edan Dus U50, CHINA) examination was performed in cases of lens and fundus examination could not be performed due to pathologies in the anterior chamber (hyphema, etc.).

Conditions that required operative treatment such as traumatic proptosis and hyphema were kept waiting until the cat became clinically more stable to being anesthetized.

Statistics

SPSS 25 (IBM Corp, 2017) statistical software was used to evaluate the data. Due to the small sample size and nonparametric data, the results were presented as median (min-max). Chi-Square Test was utilized to determine the relationship between mGCS and glaucoma (left and/or right eye). Statistical significance was accepted as $p < 0.05$.

RESULTS

Eighteen cats of different breeds, genders and ages (1 Siamese, 1 Persian, 2 British Shorthairs, 1 Scottish Fold and 13 Crossbreeds; 9 females and 9 males, mean age 12 ± 1 months) with head trauma were included in the study. In the trauma history of 18 cats; It was determined that the cause of trauma of 6 cats due to motor vehicle accidents and 9 cats due to fall from height. For the other 3 cats, cause of trauma was not known by their owners (Table 1).

The mGCS was evaluated in 3 categories as good (15-18), guarded (9-14) and grave (3-8). Out of 18 cats, 9 (50%) were grave, 8 (44.44%) were guarded, and 1 (5.56%) was good. While 4 of the traumatized cats died (mGCS grave), 14 cats (mGCS guarded-good) survived.

As a result of tomographic examination; maxillary and mandibular symphyseal separation in 2 cats (Fig 1), mandibular symphyseal separation and os temporale fracture in 1 cat, mandibular symphyseal separation in 2 cats and temporomandibular joint (TMJ) luxation in 1 cat were detected. In addition, hard palate fracture was observed in 4 cats. In our study, there was no indication to require decompressive surgery in cats with head trauma. Mandibular separations and hard palate fractures were repaired with surgical procedures. Fixation was performed with cerclage in cats with symphyseal separation. One cat with TMJ luxation were treated with close reduction followed by applied muzzle bandage. In animals with hard palate fractures, palatography was performed and a feeding tube was placed by using the pharyngostomy method. The tube was kept in place for 7-12 days.

As a result of eye examinations performed in cats with head trauma, proptosis was observed in 4 cats (22.22%) as unilaterally in 3 cats and bilaterally in 1 cat. In these cases, tarsorrhaphy was performed and the treatment was continued for 10-14 days. The lateral or medial canthus left slightly open to facilitate the application of topical ophthalmic drugs such as moxifloxacin (Vigamox®, Alcon) and artificial tears (Refresh®, Allergan) during administration. In a case of bilateral proptosis (case 14), keratoconjunctivitis sicca and corneal ulceration

occurred in the 2nd week of tarsorrhaphy (Fig 2). In the 3 cats with unilateral proptosis (cases 1, 6 and 17), there were not any complication after the tarsorrhaphy (Fig 3). Subconjunctival hemorrhage was observed in 7 cats (38.88%) as bilaterally in 2 cats (cases 4 and 16) and unilaterally in 5 cats (cases 2, 5, 7, 8 and 12). Unilateral hyphema was observed in 2 cats (11.11%) (cases 8 and 15). In these cases 1% prednisolone acetate (1 drop/eye, 4-6 times daily) (Norsol® Forte, Bilim Pharmaceuticals) as topical corticosteroid with good corneal penetration and tropicamide (1 drop/eye, twice daily) (Tropamid®, Bilim Pharmaceuticals) as mydriatic were administered. Coagulation was observed in a cat with hyphema (case 8) and the clot was removed by anterior chamber puncture directly from the limbus to prevent the resulting increase in IOP (Fig 4). Three cats had anisocoria (16.66%) (Fig 5), 2 cats had unilateral nystagmus (11.11%), and 1 cat had unilateral Horner's syndrome (5.55%). In addition, pupils were observed as mydriatic in 5 cats (27.77%) and miotic in 10 cats (55.55%). Retinal examination revealed retinal edema in 1 cat (Fig 6). After treatments for head trauma in cats anisocoria, nystagmus and Horner's syndrome resolved spontaneously. In seven cats (38,88%), IOP was found to be above 25 mmHg. In cases with increased IOP, timolol maleate (1 drop/eye, twice daily) (Timosol®, Bilim Pharmaceuticals) was administered and IOP measurements were repeated frequently (every 2-4 hours) during the treatment. Dorzolamide HCl (1 drop/eye, 3 times daily) (Cosopt®, Merck Sharp Dohme) was additionally administered in cats without normalization of IOP with treatment. In cats with glaucoma (cases 1, 4, 5, 6, 8, 14 and 17), the median mGCS was 8 (4-15), while non-glaucoma (cases 2, 3, 7, 9, 10, 11, 12, 13 and 18) the median mGCS was 9 (6-14). However, no statistical correlation was found between mGCS and glaucoma ($p>0.05$) (Table 2).

Table 1. Diagnostic evaluations of cats with head trauma

| Case | Trauma | mGCS Total score | IOP (mmHg) | | Eye Injuries | |
|------|------------------------|------------------------|------------|-------|---------------------------------------|---------------------------------------|
| | | | Left | Right | Left | Right |
| 1 | Motor vehicle accident | 4 (Grave) | 42 | 8 | Ocular proptosis | - |
| 2 | Fall from height | 9 (Guarded) | 11 | 11 | - | Subconjunctival hemorrhage |
| 3 | Fall from height | 7 (Grave) | 20 | 25 | Horner's syndrome | - |
| 4 | Unknown | 8 (Grave) | 34 | 34 | Subconjunctival hemorrhage, nystagmus | Subconjunctival hemorrhage |
| 5 | Fall from height | 12 (Guarded) | 28 | 32 | Anisocoria | Subconjunctival hemorrhage |
| 6 | Motor vehicle accident | 10 (Guarded) | 7 | 29 | - | Ocular proptosis |
| 7 | Motor vehicle accident | 12 (Guarded) | 16 | 4 | - | Subconjunctival hemorrhage, nystagmus |
| 8 | Unknown | 8 (Grave) | 19 | 29 | - | Subconjunctival hemorrhage, hyphema |
| 9 | Fall from height | 6 (Grave) | 17 | 22 | - | - |
| 10 | Motor vehicle accident | 14 (Guarded) | 9 | 14 | - | - |
| 11 | Motor vehicle accident | 6 (Grave) | 14 | 10 | | Anisocoria |
| 12 | Fall from height | 12 (Guarded) | 12 | 10 | Subconjunctival hemorrhage | - |
| 13 | Fall from height | 8 (Grave) | 13 | 9 | - | - |
| 14 | Unknown | 5 (Grave) | 48 | 39 | Ocular proptosis | Ocular proptosis |
| 15 | Motor vehicle accident | 11 (Guarded) | 13 | 14 | - | Hyphema |
| 16 | Fall from height | 12 (Guarded) | 13 | 12 | Subconjunctival hemorrhage | Subconjunctival hemorrhage |
| 17 | Fall from height | 15 (Good) | 29 | 22 | Ocular proptosis | - |
| 18 | Fall from height | 8 (Grave) | 13 | 11 | | Anisocoria |

mGCS: Modified Glasgow coma scale, IOP: Intraocular pressure

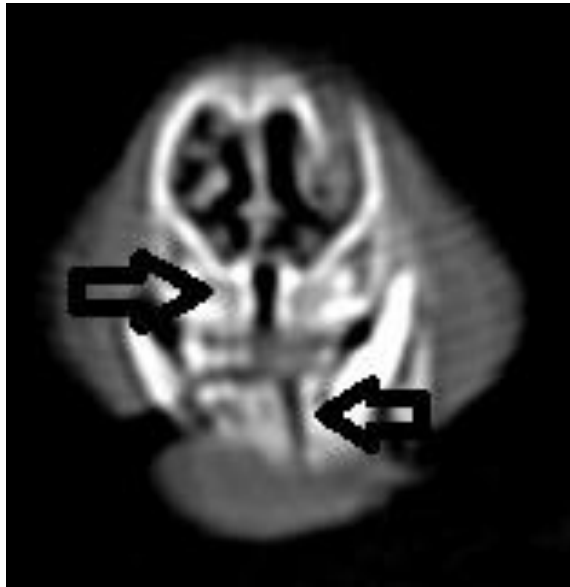

Figure 1: Case 9; maxillary and mandibular symphyseal separation (black arrow).

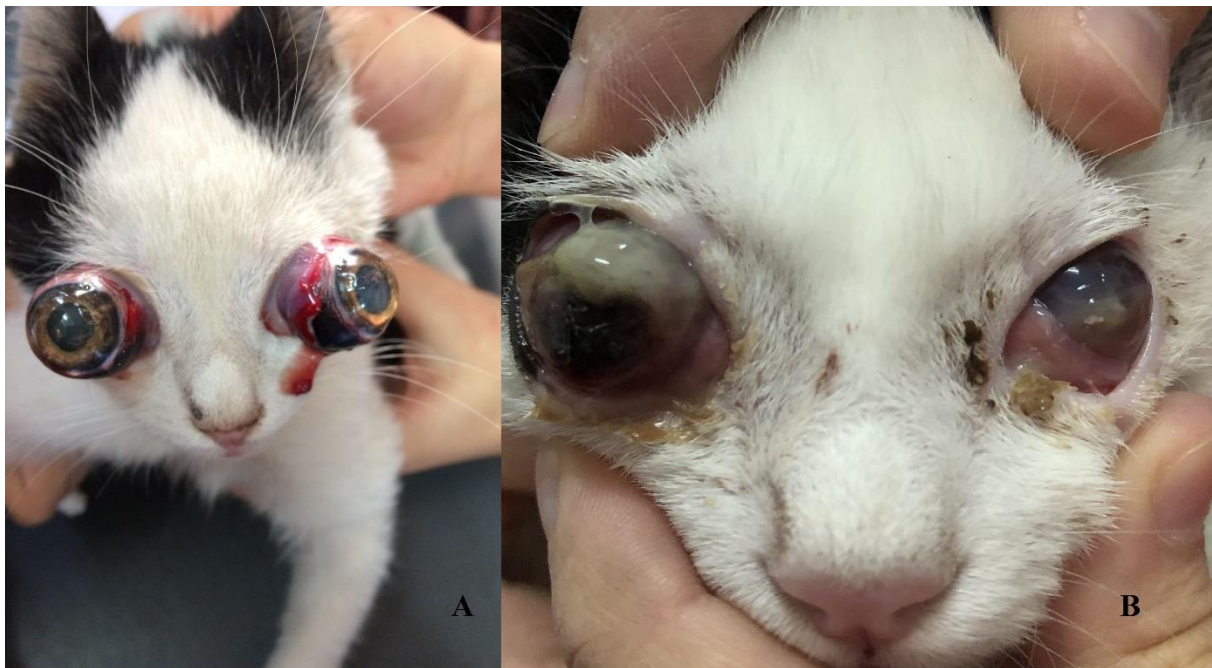


Figure 2: Case 14; bilateral ocular proptosis (A), post-op (tarsorrhaphy) 2nd week, keratoconjunctivitis sicca and corneal ulceration (B).

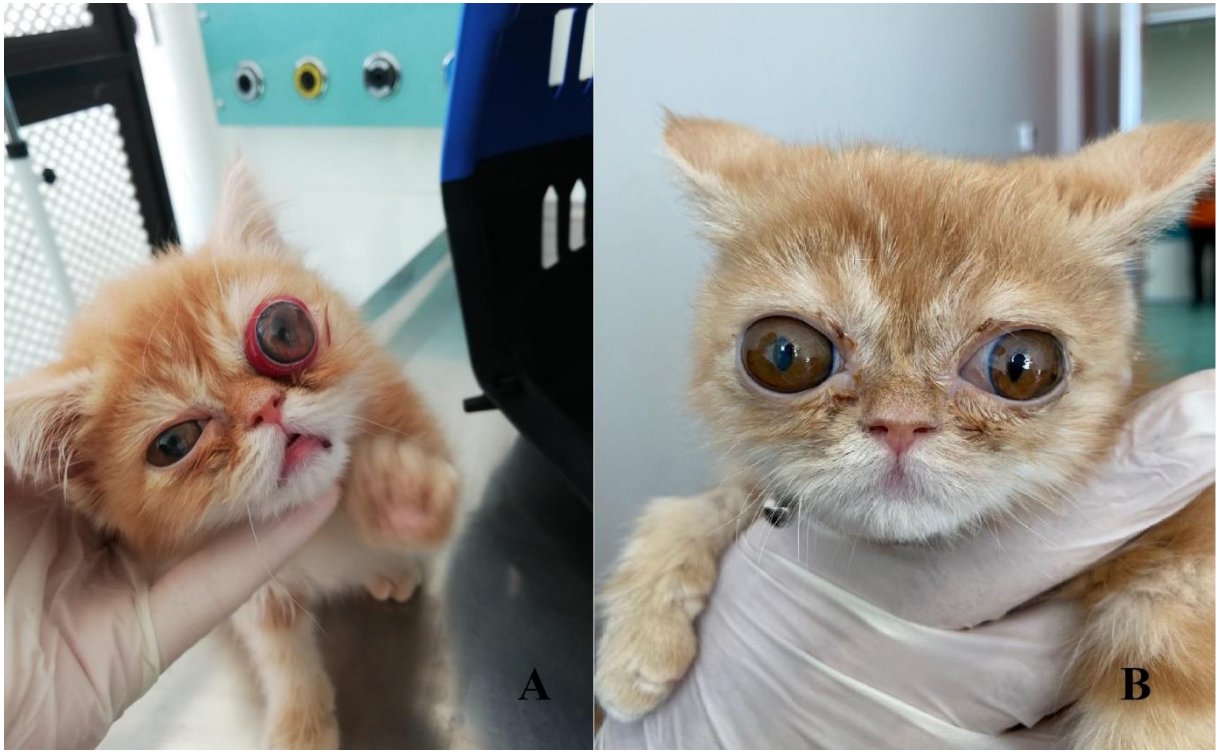

Figure 3: Case 17; ocular proptosis on the left eye (A), post-op (tarsorrhaphy) 4th week (B).

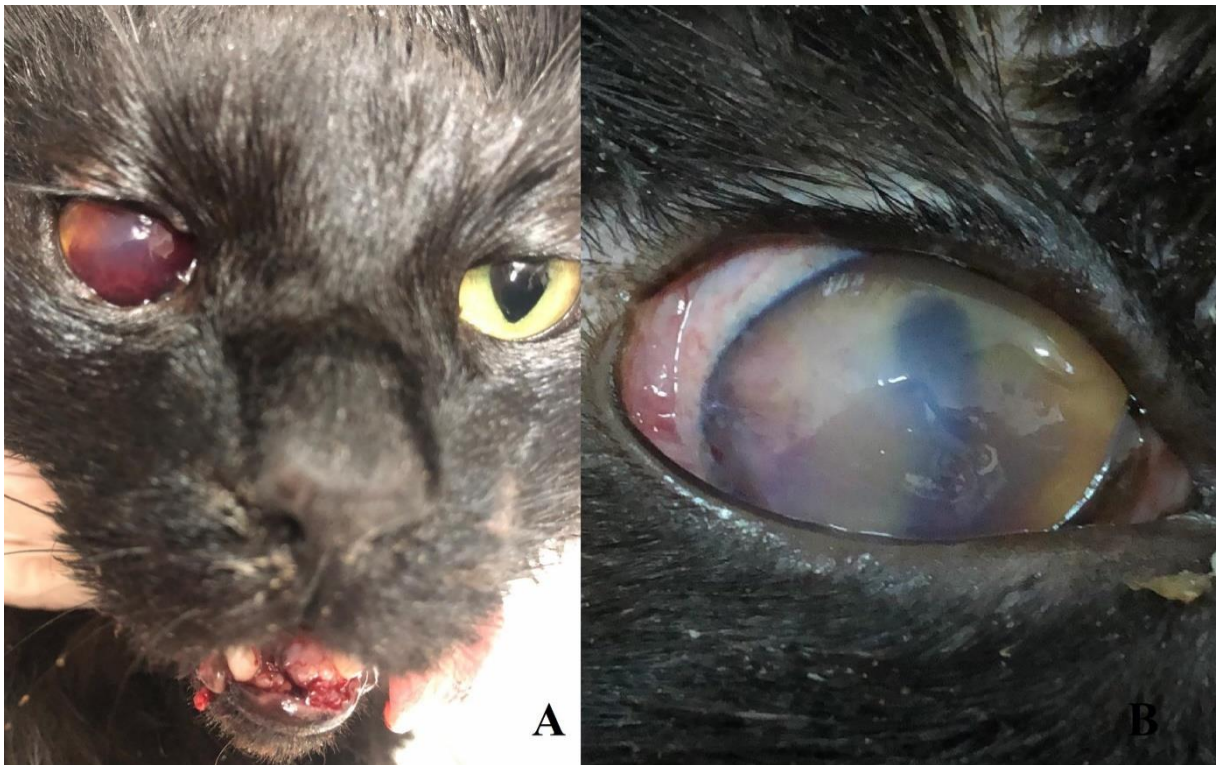


Figure 4: Case 8; unilateral hyphema (A), clot was removed by anterior chamber puncture (B).

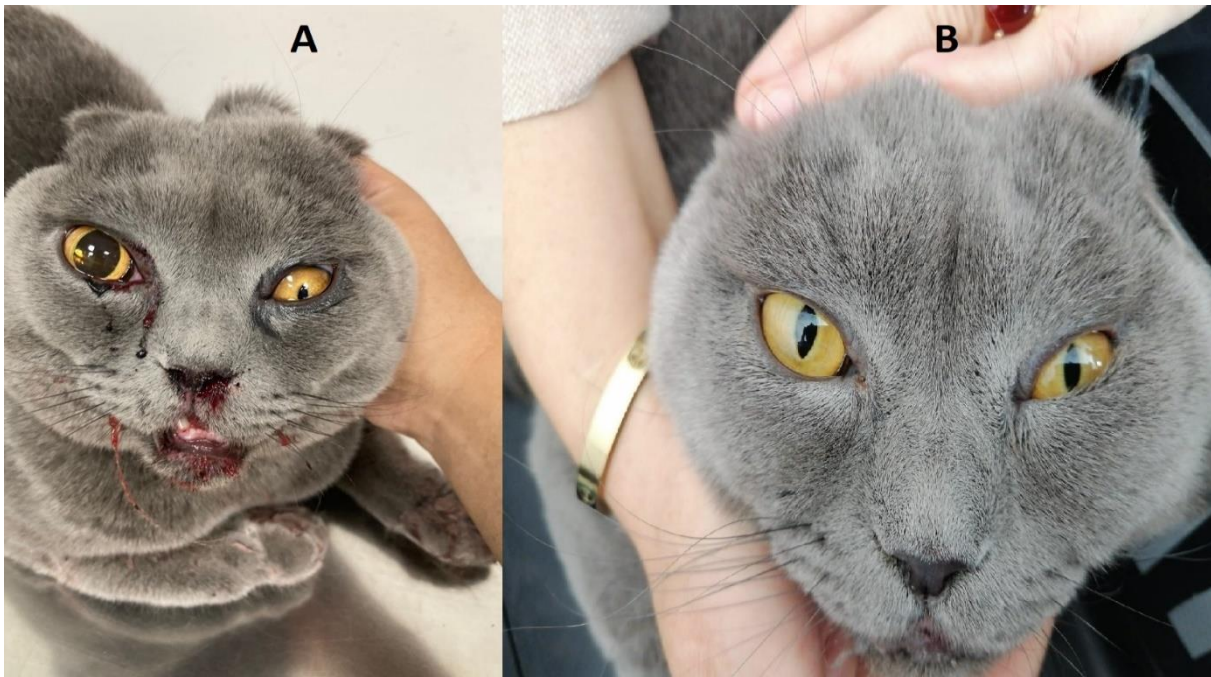


Figure 5: Case 18; Anisocoria (A), post treatment 3rd week (B).

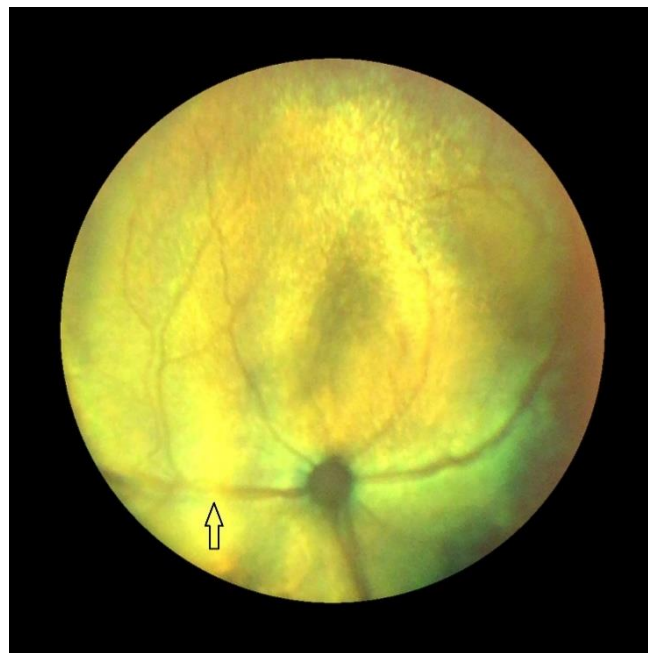


Figure 6: Case 12; retinal edema in the retinal examination (black arrow).

Table 2. Statistical correlation between mGCS and glaucoma.

| Parameter | Cats with glaucoma (n:7) | Cats without glaucoma (n:9) | P value |
|------------------------------------|-----------------------------|--------------------------------|---------|
| Modified glasgow coma scale (mGCS) | Score 8 (Score 4-15) | Score 9 (Score 6-14) | >0.05 |

DISCUSSION

Head trauma management should be aimed at restoring cerebral perfusion pressure, thus maintaining cardiopulmonary circulation, preventing increased ICP and minimizing increases in cerebral metabolic rate (Adamantos and Garosi 2011, Garosi and Adamantos 2011, DiFazio and Fletcher 2013). Therefore, treatment protocols; fluid-electrolyte (mannitol, hypertonic saline, lactate Ringer's, crystalloids, colloids), oxygenation, pain control (anesthetics, analgesics and sedatives), antibacterials, anticonvulsants and decompressive surgeries in cats with head trauma were managed according to clinical and hematological evaluations. In the study, morbidity and mortality rates were evaluated in cats with head trauma, and it was thought that the urgent sequential systemic treatment protocol was crucial. It has been reported that epistaxis, eye traumas, mandible fractures, symphyseal separation, tooth fracture and TMJ luxation are the most common clinical injuries encountered in cats with head trauma (Bonner et al. 2012). Knight and Meeson (2019) evaluated 75 cats with head injury. As a result of the study, they reported that mandibular fractures and mandibular symphyseal separations were the most common injuries (Knight and Meeson 2019). In a study conducted in 45 cats with head trauma, a high rate of mandibular symphyseal separations (25/45) was reported (Tundo et al. 2019). In our study, it was determined that the most common orthopedic problem in 18 cats with head trauma was mandibular symphyseal separation (n=5, 27.77%). This finding in our study is consistent with the aforementioned literature.

It has been reported that ophthalmoscopic examination should be performed first for the diagnosis of subconjunctival hemorrhage, which is an important finding in patients with head trauma due to it may reflect cerebral and/or meningeal hemorrhage (Laffey and Kavanagh 2002, Stocchetti et al. 2005). In this study we observed that glaucoma followed by subconjunctival hemorrhage (38.88%) as the most common eye disorders. In addition, no retrospective study has been found that on subconjunctival bleeding in cats. Saastamoinen et al (2019) evaluated 147 dogs with subconjunctival hemorrhage and they reported that 119/147 dogs had traumatic bleeding and motor vehicle accidents (47/119) were the most common causes of trauma. In our study, subconjunctival hemorrhage was observed in 7 cats (38.88%) and the cause of the trauma was found to fall from a height (4/7). However, the findings of the current study do not support that study (Saastamoinen et al. 2019). Possible explanation for this controversy may be the lack of adequate number of cases and differentiation of the species. However, subconjunctival hemorrhage occurred in both animal species is due to the trauma (motor vehicle accident,

fall from a height) that those species are the most exposed.

Head trauma can cause intracranial hemorrhage or increased pressure. In both cases, a compression can occur in the brain. Parasympathetic dysfunction may occur as a result of compression at the oculomotor nerve which is the third of the cranial nerves and arises from the midbrain. The symmetry of the trauma causes both pupils to be constricted. While asymmetrical, only the pupil on the affected side becomes constricted and resulting in anisocoria. If the compression on the brain cannot be prevented, the constricted pupils become dilated and the pupillary light reflexes disappear. This clinical sign reports that the prognosis of the patient is poor (Barnes Heller and Bentley 2016). As a result of the evaluation in this study, 3 out of 5 cats with dilated pupils were died. It has been observed that dilated pupils in cats with head trauma show the presence of serious damage on the brain and that the mortality rate may be high in these cases, which is consistent with the literature. Therefore, urgent treatment options focused to brain damage should be evaluated in animals with dilated pupils.

In head traumas, increased IOP may occur, usually secondary to cases of anterior uveitis, hyphema and proptosis. It has been reported that post-traumatic IOP increase occurs when the trabecular network is occluded by clots, inflammatory or red blood cells (Kaur et al. 2014). In our study, proptosis was found in 4 of the 7 cats with increased IOP, and hyphema was found in 1 cat (case 8). In the other cat with hyphema (case 15), IOP was measured at normal range. This situation can be explained by the fact that the hyphema was partial and coagulation was not occurred, and the trabecular meshwork was not occluded, which is consistent with the literature. However, in the presence of severe hyphema and coagulation, the need for surgical intervention should not be ignored.

Common findings in cases with mild proptosis were mild exophthalmos, conjunctival inflammation, mild corneal damage, and normal or reduced pupillary light reflex. In addition, these patients may have different degrees of loss of vision (Mandell and Holt 2005). In cases with more severe proptosis, exophthalmos is more prominent, there is significant tearing of the ocular muscles and optic nerve, hyphema may have formed, severe drying of the ocular structures, corneal rupture and/or rupture of the bulbus oculi, and severe pain. The prognosis is poor in terms of restoring of loss of vision in these patients. Potential complications associated with proptosis include persistent strabismus, ulcerative keratitis, keratoconjunctivitis sicca, neuroretinal degeneration, and phthisis bulbus (Wheler et al. 2001, Mandell and Holt 2005). In our evaluation, mild proptosis was formed in 1 cat (case 17) and pupillary light reflex was weak. No postoperative complications were observed as a result of tarsorrhaphy. However, severe proptosis

was observed in 1 cat (case 14). There was no the pupillary light reflex and pupillary dilatation was observed in this cat. With the guidance of the patient owner, bilateral tarsorrhaphy was performed instead of enucleation, and keratoconjunctivitis sicca and ulcerative keratitis occurred in the 2nd postoperative week. These complications were observed in accordance with the literature, and the poor prognosis in severe proptosis cases made us think that the enucleation option should be evaluated.

CONCLUSION

The results of this study indicate that glaucoma, subconjunctival hemorrhage and proptosis are the most common pathologies in cats with head trauma and these pathologies should not be ignored during the intervention of the head trauma patients. In cases of the eye problems such as anisocoria, Horner's syndrome and nystagmus were not resolve spontaneously during treatment, the treatment protocol should be reassessed. In addition, it is thought that irreversible loss of vision can be prevented by frequently repeated IOP measurements, regardless of the mGCS score, in cases with head trauma.

Conflict of interest: The authors declare that there is no actual, potential or perceived conflict of interest for this article.

Ethical statement: This study was approved by the Selçuk University, Faculty of Veterinary Medicine, Laboratory Animal Production and Research Center Ethics Committee (SUVDAMEK) (2019/83). Patient owners of all cases signed an informed consent form.

Financial support: Supported by the Coordination of Scientific Research Projects of Selçuk University (BAP) (No. 19401153).

REFERENCES

- Adamantos S, Garosi L.** Head trauma in the cat: 1. Assessment and management of craniofacial injury. *J Feline Med Surg.* 2011; 13(11):806–814.
- Barnes Heller H, Bentley E.** Neurologic causes of canine anisocoria. *Today's Vet Pract.* 2016; 77–83.
- Bonner SE, Reiter AM, Lewis JR.** Orofacial manifestations of high-rise syndrome in cats: A retrospective study of 84 cases. *J Vet Dent.* 2012; 29(1):10–18.
- Dewey C, Fletcher D.** Head-trauma management. In: *Practical Guide to Canine and Feline Neurology*, Ed; Dewey C, da Costa RC, 3rd Ed., Wiley Blackwell, 2015; pp. 237–248.
- DiFazio J, Fletcher DJ.** Updates in the management of the small animal patient with neurologic trauma. *Vet Clin North Am Small Anim Pract.* 2013; 43(4):915–940.
- Garosi L, Adamantos S.** Head trauma in the cat: 2. Assessment and management of traumatic brain injury. *J Feline Med Surg.* 2011; 13(11):815–823.
- Kaur S, Kaushik S, Singh Pandav S.** Traumatic glaucoma in children. *J Curr Glaucoma Pract.* 2014; 8(2):58–62.
- Knight R, Meeson RL.** Feline head trauma: a CT analysis of skull fractures and their management in 75 cats. *J Feline Med Surg.* 2019; 21(12):1120–1126.
- Kuo KW, Bacek LM, Taylor AR.** Head trauma. *Vet Clin North Am Small Anim Pract.* 2018; 48(1):111–128.
- Laffey JG, Kavanagh BP.** Hypocapnia. *N Engl J Med.* 2002; 347(1):43–53.
- Mandell DC, Holt E.** Ophthalmic emergencies. *Vet Clin North Am Small Anim Pract.* 2005; 35(2):455–480.
- McLellan GJ, Miller PE.** Feline glaucoma—a comprehensive review. *Veterinary ophthalmol.* 2011; 14(1): 15–29.
- Opperman E.** Head trauma in the feline patient – an update. *Vet Nurs J.* 2014; 29(6):194–197.
- Platt S.** Treatment options for head trauma patients. *33rd World Small Anim Vet Congr. Dublin: WSAVG;* 2008.
- Platt S, Olby N.** Neurological emergencies. In: *BSAVA Manual of Canine and Feline Neurology*, Ed; Platt S, Olby N, 4th Ed., BSAVA. 2004; pp. 320–336.
- Platt S, Radaelli S, McDonnell J.** The prognostic value of the modified Glasgow coma scale in head trauma in dogs. *J Vet Intern Med.* 2001; 15(6):581.
- Rochlitz I.** Clinical study of cats injured and killed in road traffic accidents in Cambridgeshire. *J Small Anim Pract.* 2004; 45(8), 390–394.
- Rusanen E, Florin M, Hassig M, Spiess BM.** Evaluation of a rebound tonometer (Tonovet) in clinically normal cat eyes. *Vet Ophthalmol.* 2010; 13(1): 31– 36.
- Saastamoinen J, Rutter CR, Jeffery U.** Subconjunctival haemorrhage in 147 dogs. *J Small Anim Pract.* 2019; 60(12):755–760.
- Sande A, West C.** Traumatic brain injury: a review of pathophysiology and management. *J Vet Emerg Crit Care.* 2010; 20(2):177–190.
- Stocchetti N, Maas AIR, Chieregato A, van der Plas AA.** Hyperventilation in head injury. *Chest.* 2005; 127(5):1812–1827.
- Tundo I, Southerden P, Perry A, Haydock RM.** Location and distribution of craniomaxillofacial fractures in 45 cats presented for the treatment of head trauma. *J Feline Med Surg.* 2019; 21(4):322–328.
- Wheler CL, Grahn BH, Pocknell AM.** Unilateral proptosis and orbital cellulitis in eight African hedgehogs (*Atelerix albiventris*). *J Zoo Wildl Med.* 2001; 32(2):236–241.