

Feline Eosinophilic/Proliferative Keratitis: A Retrospective Study

Aynur DEMİR

Istanbul University- Cerrahpaşa, Veterinary Faculty, Surgery Department, 34315 Avcılar, Istanbul, Turkey

ABSTRACT

The medical records of 35 cats (44 eyes) with feline eosinophilic keratitis (FEK) diagnosed between 2016 and 2021 were reviewed. The mean age at the presentation of cases diagnosed with FEK was 4.12 years (3 months-13 years). Domestic shorthair was the dominant breed, accounting for 68.57% of cats (24/35). FEK was unilateral in 74.28% of the cases, and the most frequently affected position was the superotemporal quadrant of the cornea (75% of the eyes). The cytological examination of the cornea and conjunctiva showed a mixture of multiple eosinophils, plasma, and mast cells, confirming the diagnosis of FEK. Eosinophils were found in 86.36% of the corneal and conjunctival scrapings. We performed the polymerase chain reaction test for feline herpes virus type 1 in 12/35 cats. Viral DNA was detected in 20% of these cats. The cats were treated with a subconjunctival corticosteroid, a topical antibiotic-corticosteroid combination, artificial tear drops, and antiviral gel containing ganciclovir. At one to two weeks after the initial examination, the clinical signs markedly improved. The controlled and regular use of topical corticosteroids brought the lesions under control and resolved FEK without recurrence at least for six months.

Keywords: Eosinophilic, Feline, Keratitis, Proliferative, Steroids.

Kedilerde Eozinofilik/Proliferatif Keratitis: (2016-2021) Retrospektif Çalışma

ÖZ

2016 ve 2021 yılları arasında teşhis edilen 35 eozinofilik keratitisli kedi (FEK) vakasının (44 göz) tıbbi kayıtları gözden geçirildi. FEK tanısı konulan olguların ortalama sunum yaşı 4,12 yıldır (3ay-13 yıl). Domestik shorthair, kedilerin (24/35) %68.57'ni oluşturan baskın cinstir. Durum, vakaların %74,28'sinde tek taraflıydı ve en sık etkilenen pozisyon korneanın superotemporal kadranıydı (gözlerin %75'i). Kornea ve konjunktivanın sitolojik incelemesi, FEK tanısını doğrulayan çok sayıda eozinofil, plazma ve mast hücresi karışımı gösterdi. Eozinofiller, korneal ve konjunktival kazımların %86.36'sında bulundu. 12/35 kedi için kedi herpes virüsü tip 1 (FHV-1) için polimeraz zincir reaksiyonu (PCR) gerçekleştirdik. Bu kedilerin %20'sinde viral DNA tespit edildi. Kediler subkonjunktival kortikosteroid, topikal bir antibiyotik-kortikosteroid kombinasyonu, suni göz yaşı damlası ve gansiklovir içeren antiviral jel ile tedavi edildi. İlk muayene edildikten 1-2 hafta sonra klinik belirtiler dikkate değer bir şekilde iyileşti. Kontrollü ve düzenli topikal kortikosteroid kullanımı lezyonu kontrol altına aldı ve en az 6ay boyunca hastalığı nüks etmeden çözdü.

Anahtar kelimeler: Eozinofilik, Kedi, Keratitis, Proliferatif, Steroidler.

To cite this article: Demir A. Feline Eosinophilic/Proliferative Keratitis: A Retrospective Study. Kocatepe Vet J. (2022):15(2):167-181

Submission: 11.10.2021 **Accepted:** 14.03.2022 **Published Online:** 18.04.2022

ORCID ID: AD: 0000-0002-5471-1655

*Corresponding author e-mail: aynurdemir_1903@hotmail.com

INTRODUCTION

Feline eosinophilic keratitis (FEK), also known as proliferative keratitis, proliferative eosinophilic keratitis, or eosinophilic plaque, is a slowly progressive infiltrative keratopathy that starts with a progressive and superficial vascularization of the perilimbal cornea and is characterized by the infiltration of the corneal epithelium and stroma by mast cells, eosinophils, neutrophils, lymphocytes, and plasma cells (Ahn et al. 2010, Dean and Meunier 2013, Edwards et al. 2015, Lucyshyn et al. 2021). Although an association between FEK and feline herpes virus type 1 (FHV-1) has been suggested in cats, the precise pathogenesis of FEK remains unknown, and the cellular profile is typically consistent with type I (IgE-mediated) or type IV (Hodges 2005, Romanek and Sebbag 2021). The literature also contains views suggesting a connection between this condition and the feline eosinophilic granuloma complex (Chisholm 1989).

Although the diagnosis of FEK is based on pathognomonic findings during the ophthalmic examination, the definitive diagnosis is confirmed by corneal cytology (Chisholm 1989, Spiess et al. 2009, Edwards et al. 2015). Treatment options vary and often involve a long-term process. Various drug combinations can be tried until the most effective treatment protocol is determined (Spiess et al. 2009). Treatment recommendations usually include corticosteroids and/or megestrol acetate. Initially, the use of topical or subconjunctival corticosteroids is recommended, and if this treatment fails, megestrol acetate may be required (Chisholm 1989).

This retrospective study aimed to investigate the breeds, age range, and clinical and cytological features of cats with FEK and determine the efficacy of corticosteroid and antiviral topical formulations in the treatment of the disease. The hypothesis was that corneal lesions would regress with the use of topical corticosteroids and recurrence would occur when this treatment was discontinued, but the systemic side effects of oral formulations, such as megestrol acetate would not be observed.

MATERIAL and METHODS

The records of cats referred to xxxxxx between January 2016 and April 2021 and were diagnosed with FEK were reviewed. The cats were included in the sample based on a confirmed diagnosis of FEK through the corneal cytology identification of inflammatory cells, such as eosinophils, mast, and plasma cells. The definitive diagnosis of FEK was made based on clinical examination findings and presence of eosinophils in corneal cytology.

Animals

The study material consisted of 35 cats of different breed, age, and sex characteristics, which were referred to our clinic between January 2016 and April 2021 and diagnosed with uni/bilateral FEK based on ophthalmoscopic findings, pathognomonic appearance of the ocular surface, and cytological examination. Only the cases that were registered in the system were included in the sample.

Methods

Data including breed, age, sex, ophthalmological findings, affected eye(s) and duration, location of the lesion, clinical status of the cases, diagnostic tests, medical treatment and time to resolution, and recurrence status were recorded. The distribution of FEK cases according to age group, breed, sex, duration, and eye is presented in table 1 and the distribution of lesion localization, cytology and clinical findings are reported in table 2. After obtaining the detailed anamnesis of the cases, physical and ophthalmological examinations were performed. The cases underwent a complete ophthalmic examination, including topical fluorescein staining, Schirmer's tear test, intraocular eye pressure measurement with tonometry (TonoVet, Kruuse, USA), indirect ophthalmoscopy after mydriasis (tropicamide ophthalmic solution), and fundus examination. The ophthalmoscopic examination revealed blepharospasm, ocular discharge, conjunctivitis, corneal opacity, and superficial vascularization, and cobblestone-like pink plaques affecting the cornea in varying locations (Fig 1). While the clinical diagnosis was tentatively based on the characteristic appearance of corneal lesions, e.g., proliferative, white-pink, edematous, irregular, and vascularized tissue and white-yellow corneal plaques (Fig 2), the definitive diagnosis was made upon the cytological examination of corneal/conjunctival scrapings, based on the presence of inflammatory cells, such as eosinophils, masts, plasma supporting the provisional diagnosis of FEK (Fig 3). Diagnostic tests performed included the cytological examination of corneal (Fig 4) and conjunctival specimens and real-time quantitative polymerase chain reaction (PCR) test for FHV-1. For the cytological evaluation, specimens were scraped from the cornea and conjunctival regions with pink and white plaques using a blunt-tipped corneal knife or cotton-tipped swabs with the cats under local anesthesia. The specimens spread on slides were air dried and stained with Diff-Quik. The cytological examination was performed using a light microscope at 40x magnifications. Lesion localizations in the cornea were classified as the relevant corneal quadrant (superotemporal (Fig 5), or inferonasal (Fig 6), central area, or whole cornea if the lesions covered most of

the corneal surface, as described by Dean and Meunier.

Treatment

Written informed consent to accept medical treatment was obtained from each guardian prior to initiating medical treatment. After local anesthesia, first topical dexamethasone (Decort, Deva, Turkey) was administered to all the eyes using a subconjunctival insulin injector of 2-4 mg per eye. In eyes where proliferative lesions were accompanied by corneal ulcers (10/35), a topical antibiotic ofloxacin (Exocin, Abdi İbrahim, Turkey, two drops for three to six times) and artificial tear drops (sodium hyaluronate (Dryex, Abdi İbrahim, Turkey, two drops for three to six times) and antiviral topical ointment ganciclovir (Virgan, Fharmila-thea, Turkey, two times) were applied.

For all the eyes without corneal ulcer or those with healed accompanying ulcers, moxifloxacin, and dexamethasone (Moxidexia®, Abdi İbrahim, Turkey, two drops for four to six times), sodium hyaluronate (Dryex, Abdi İbrahim, Turkey, two drops for four to six times) and 1.5 mg ganciclovir ointment (Virgan, Thea Pharma, Turkey, twice a day) were prescribed as the same treatment protocol.

In all the cases, positive results were obtained with medical treatment over varying durations, with the treatment lasting longer in some, but the use of immunosuppressive agents other than subconjunctival and topical steroids was not required in any of the cats. Despite the intensive and long-term use of topical steroids, including FHV-1 positive cases, none developed any complication (corneal infection, deep ulcer, or melting ulcer). Follow-up examinations were recommended at the first, second and four weeks after starting treatment. When the clinical complaints disappeared, topical steroids were continued for a minimum of three weeks to a maximum of two months to eliminate the possibility of recurrence. The frequency of treatment was gradually reduced depending on the response and severity of the initial disease. This reduction was typically undertaken after the complete resolution of lesions, with the daily treatment frequency being decreased to one dose per week (Fig 7 (a,b,c)). Photographs of the eyes were taken at each visit to assess the changes (Fig 8 (a,b)). After the lesions healed, follow-up evaluations were performed at the second, sixth, 10th and 12th months, two and three years. The guardians of the cats that were not referred for a follow-up visits were contacted by phone, and information about the clinical status of the cases and photographs of the final appearance of the eyes were obtained.

RESULTS

Signalment

During the five-year study period, 35 cats (44 eyes) were diagnosed with FEK and treated. The mean age of the affected cats at the time of diagnosis was 4.12 years, and the age range ranged from three months to 13 years. There was male 23 (65.71%) and 12 (34.28%) female cats, of which five and four were non-sterile, respectively. Domestic cats, both shorthair and longhair, were the most affected breeds (82.85%, 29/35). In addition, three other breeds were also represented, namely Siamese (5.71%, 2/35) (Fig 9), British Shorthair (5.71%, 2/35), and Persian (5.71%, 2/35) (Fig 10).

Clinical findings

In most cats, only one eye was affected (74.28%, 26/35). The left eyes were more frequently affected than the right eyes (18/35 versus 8/35). Nine cats had bilateral lesions, of which eight had lesions in both eyes at presentation, while one cat developed eosinophilic lesions in the left eye at one year after presentation. Corneal lesions were most found in the superotemporal quadrant of the cornea (75%, 33/44), followed by the inferonasal quadrant (18.18%, 8/44) (Fig 11) and less frequently in the central surface (6.8%, 3/44). In two cases with lesions in the inferonasal quadrant, lesions were also seen in the nictitating membrane. It was determined that the proliferative lesions started from the limbal region in two cases (Fig 12) with the involvement of the superotemporal quadrant and three cases with that of the inferonasal quadrant and covered a very large area of the corneal surface starting from the limbal region and progressing toward the central cornea. Three cases had a history of stomatitis and mandibular sequester in addition to ocular lesions. The mean duration of clinical complaints was 2.47 months (range, 1 week-3 months). In three cats, clinical complaints had first started one or two years earlier and recurrence occurred a few weeks before the cases were referred to our department.

The preliminary diagnosis of the lesions was based on the clinical presentation and/or anamnesis of the cases. All the cases had corneal vascularization and infiltration. The eyes that were classified as minimally affected (11/44, 25%) had mild superficial corneal vascularization, edema, and/or fibrosis without plaque (Fig 13). In mildly, moderately, and severely affected eyes, there were plaques with or without corneal changes, covering approximately >25% (33/44, 75%), 26-75% (9/44, 20.45%), and 76-100% (2/44, 4.54%) of the cornea, respectively. Sandy-white corneal plaques were evident in 30 eyes (68.18%) of the 26 cats (Fig 14). A history of corneal ulceration before disease onset was recorded in 7/44

eyes (15.90%; 7/35 cats, 20%). At the time of diagnosis, 10/44 eyes (22.72%; 10/35 cats, 28.57%) had lesions and surrounding corneal ulcers. Of all the 35 cats diagnosed with FEK, 24 (68.57%) presented with additional conjunctivitis, and 17 eyes of 16 cases had non-healing corneal ulceration.

Cytological findings

Corneal and/or conjunctival cytology was performed in all the cases. Among the 44 eyes of 35 cats, eosinophils were detected in 38 (86.36%), mast cells in 25 (56.81%), plasma cells in 14 (31.81%), neutrophils in 28 (63.63%), and lymphocytes in six (13.63%).

Results of the PCR test for FHV-1

Twelve of the 35 cats were tested for FHV-1 using the PCR (tears) test. DNA was detected in 50% (6/34, 5 males and 1 female) of these cats, while 50% (6/34, 3 males and 3 females) did not have FHV-1. The remaining 23 cats were not tested for various reasons, such as the guardian's financial constraints and refusal of the test.

Treatment and Outcomes

All the 35 cats positively responded to treatment, evidenced by a reduction in the size of the lesions or disappearance of eosinophilic plaques, regression of

corneal vascularization, and resolution of the previously described fluorescein-positive areas (Fig 15(a,b)). Healing times with topical medical treatment ranged from 12 days to 4 months, with a mean duration of 1.2 months. At the follow-up sessions undertaken at one-week intervals, significant regression of the corneal lesions was seen in 20.45% of the eyes at the first follow-up (10-14 days), 27.27% at the second follow-up (15-21 days), 29.54% at the third follow-up (21-30 days), and 22.72% at the fourth follow-up (30-45 days and later). Three of the 35 cats made slow but gradual improvement, and their problem was eventually resolved within two to three months. The cases were followed up for a period of six months to three years after recovery. Corneal lesions reappeared in 11.76% of the cats within six months to one year. All the recurrences resulted from the discontinuation of treatment by the guardians. Response to topical steroid treatment took a long time in 6.81% of the cats. Blepharospasm and epiphora were observed in three cases, although their clinical complaints were not the same. Mild corneal scarring was observed in some of the cases (37.14%, 13/35) despite chronic topical steroid treatment. The frequency of treatment required to maintain remission varied between the cats. Three of the 35 cats relapsed when treatment was discontinued. All these cats responded to treatment when the treatment was started again.

Table 1. Distribution of FEK cases according to the age group, sex, breed, duration, and eye

Item	n	%
Age group (yrs)		
≤1	9	25.71
1- ≤ 5	19	54.28
5-10	4	11.42
≥10	3	8.57
Sex		
Male	23	65.71
Female	12	34.28
Breed		
Domestic Shorthair	24	68.57
Domestic Longhair	5	14.28
Siamese	2	5.71
British Shorthair	2	5.71
Persian	2	5.71
Duration		
2-3 weeks	14	35
4-6 weeks	17	48.57
7+ weeks	4	11.42
Eye		
Left	18	51.42
Right	8	22.85
Both	9	25.71
TOTAL	35	100

Table 2. Distribution of lesion localisation, cytology, and clinical signs in FEK cases

Item	n(eyes)	%
Affected tissue/s		
Co	14	31.81
Conj	1	2.27
Co+Conj	27	61.36
Co+NM	2	4.54
Lesion location		
ST	33	75
IN	8	18.18
C	3	6.81
Cytology		
E	38	86.36
M	25	56.81
P	14	31.81
N	28	63.63
L	6	13.63
Clinical signs		
PL	32	72.72
H	31	70.45
V	37	84.09
ED	38	86.36
U	10	22.72

Co: Cornea, Con: Conjunctiva, IN: Inferonasal, ST: Superotemporal, C: Central, NM: Nictitans membrane, E: Eosinophil, M: Mast cells, P: Plasma cells, N: Neutrophil, L: Lymphocyte, PL: Plaque, H: Hyperemia, V: Vascularization, ED: Edema, UL: Ulcer

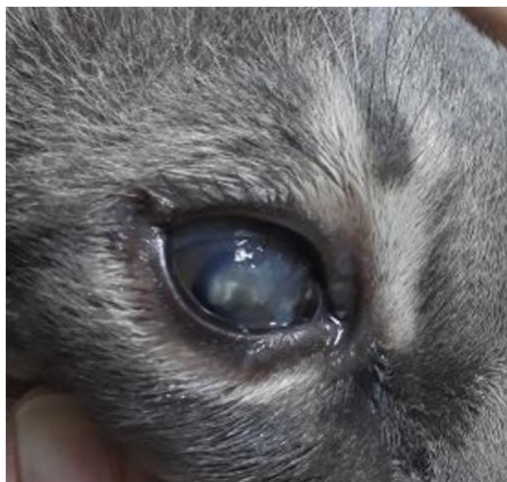

Figure 1. Cobblestone lesions covering the large surface of the cornea in a cat. (Case 13).

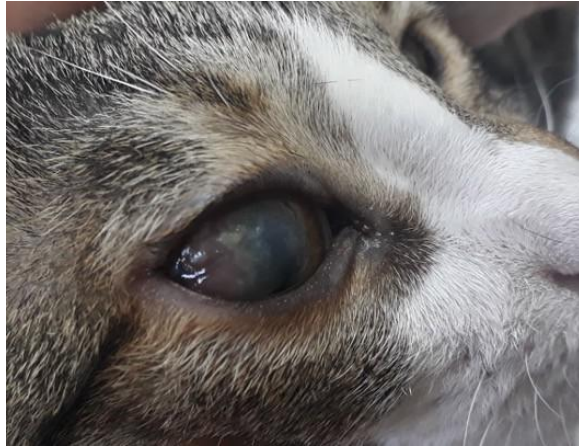

Figure 2. Corneal edema, irregular vascularized tissue, and white-yellow corneal plaques in a cat. (Case 9).

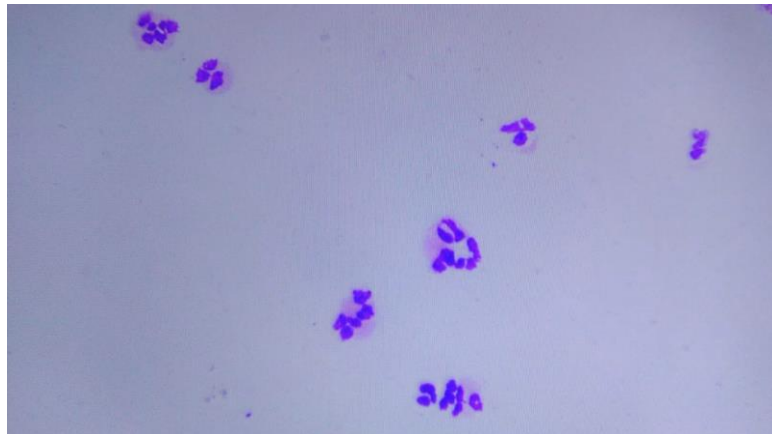


Figure 3. Corneal scraping of the left affected eye showing eosinophil and neutrophil. Diff-Quick staining, 40x magnification.

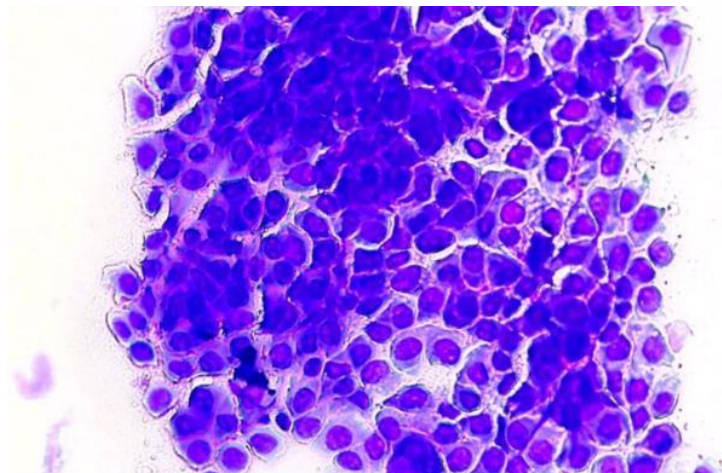


Figure 4. Superficial corneal epithelial cell deposits on cytological examination.

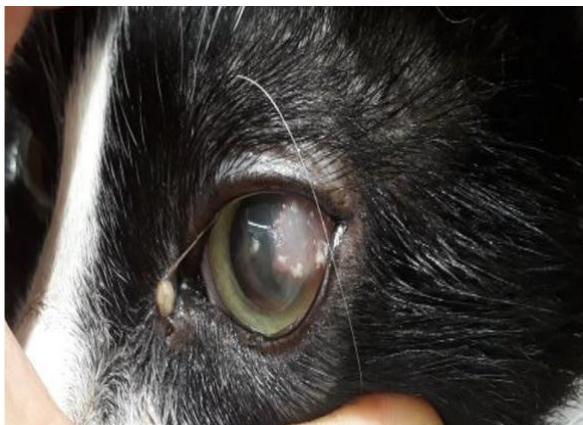


Figure 5. Gross appearance of feline eosinophilic keratitis as white plaques that partially cover superotemporal quadrant of the left eye in a 2-year cat.



Figure 6. White plaque and neovascularization on the inferonasal quadrant of the cornea of the left eye in a 2-year-old Domestic longhair cat.

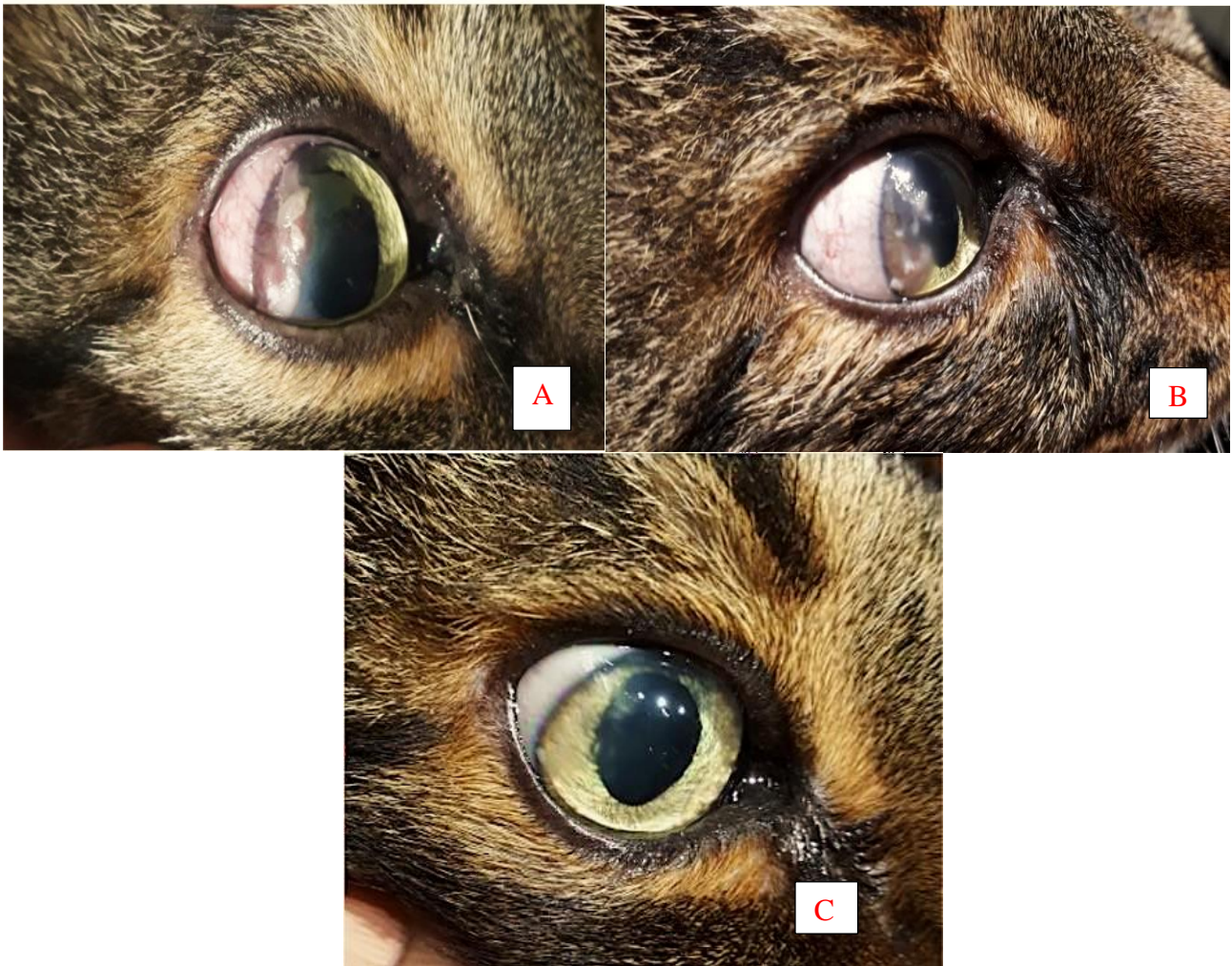


Figure 7. A. First appearance of eosinophilic keratitis in the right eye of a 13-year-old Domestic shorthair cat. B. 12 days with 1% topical dexamethasone, C. Appearance after 3 weeks of treatment.

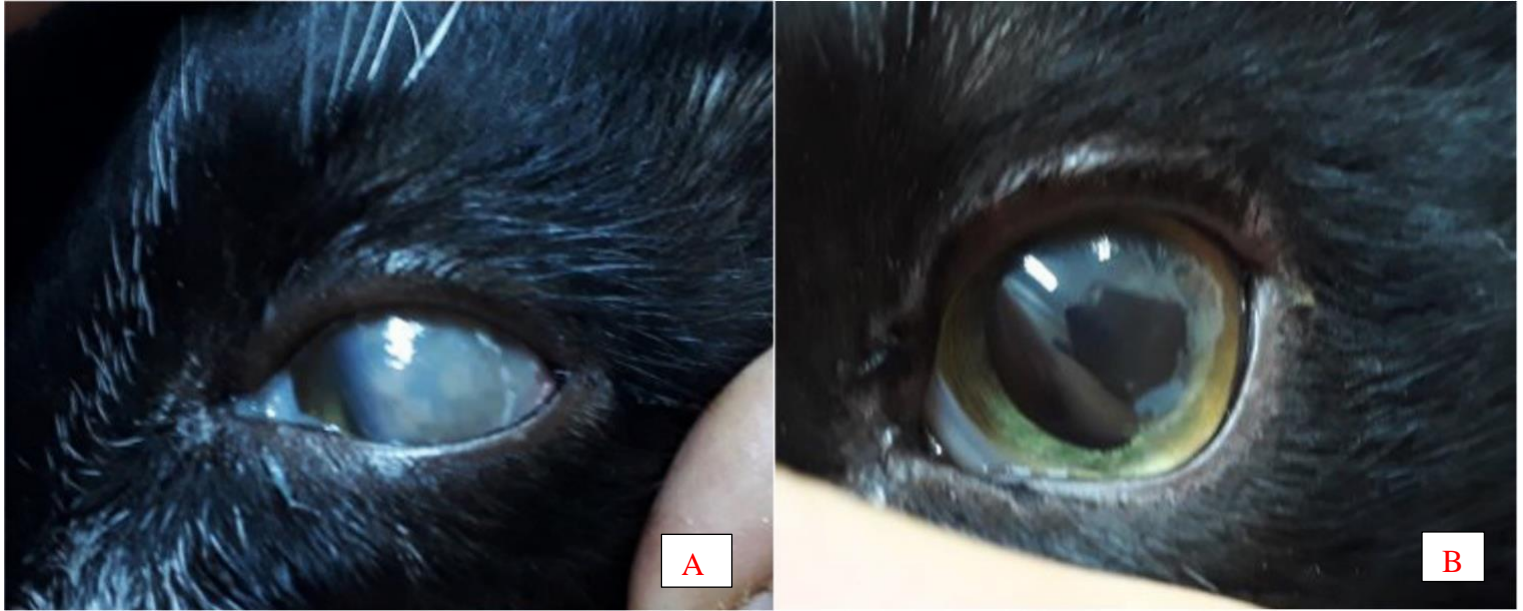


Figure 8. A. First appearance of the eosinophilic plaque covering the large part of the left cornea of case 6. B. Appearance of the left cornea after 4 weeks of treatment with 1% topical dexamethasone.

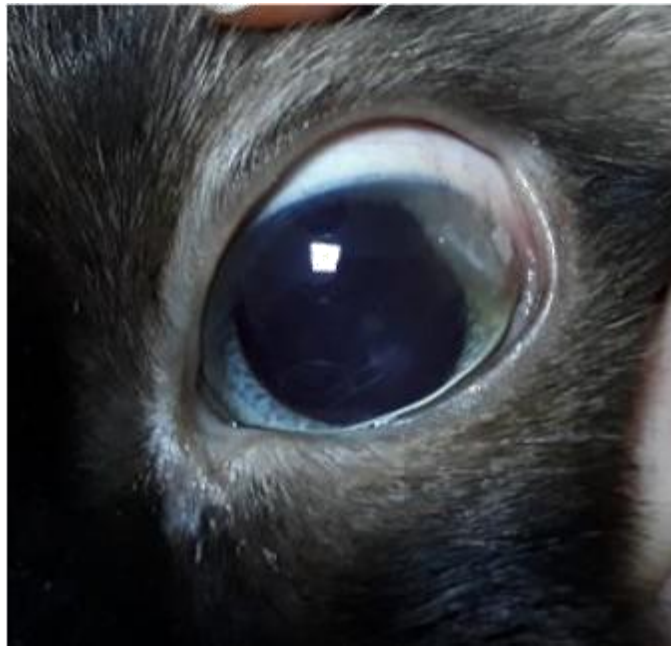

Figure 9. Corneal vascularization and mild plaque in the superotemporal quadrant in a 10-year-old Siamese cat.

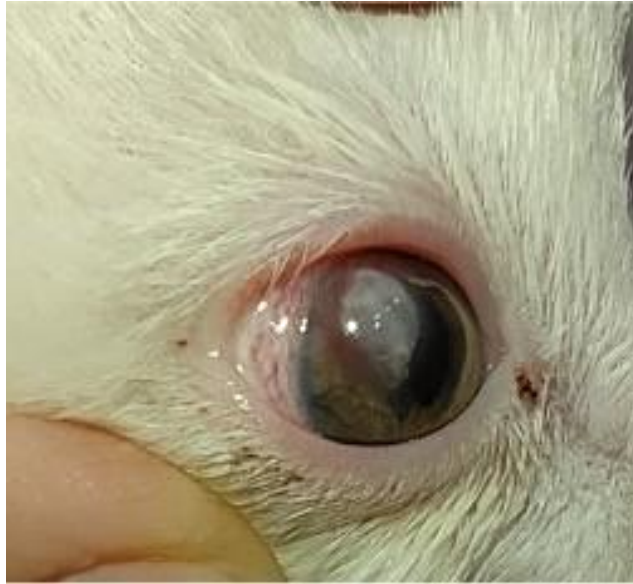

Figure 10. Corneal plaque and neovascularization in the right corneal superotemporal quadrant in a 3-month-old Persian cat.

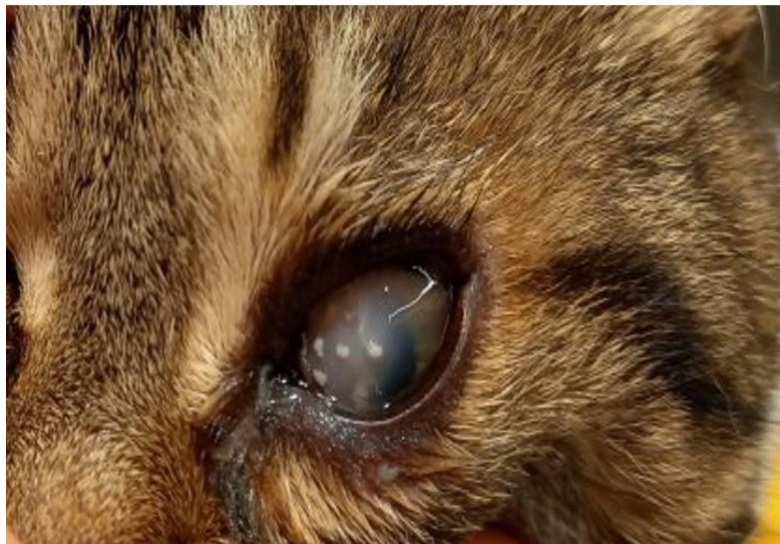


Figure 11. Feline eosinophilic keratitis. Note the raised white corneal plaques and dense corneal edema.

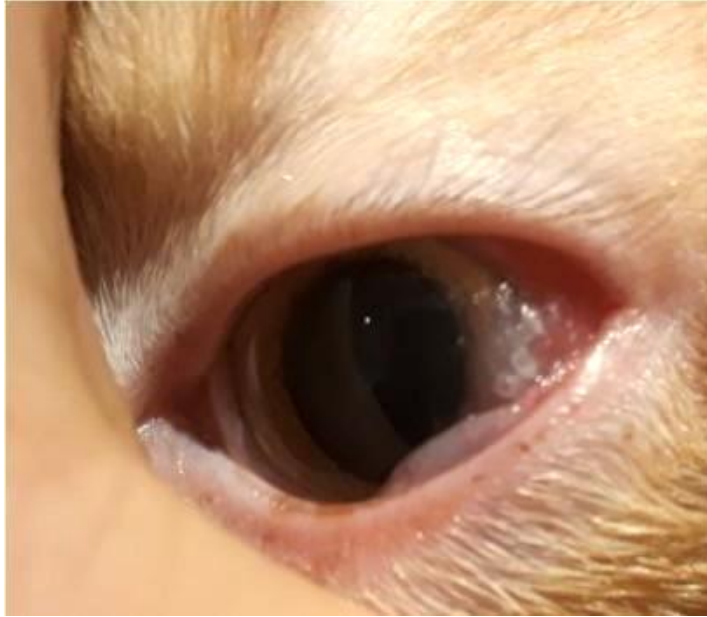

Figure 12. Corneal white plaques and conjunctival hyperemia originating in the limbal region in a one-year-old cat.

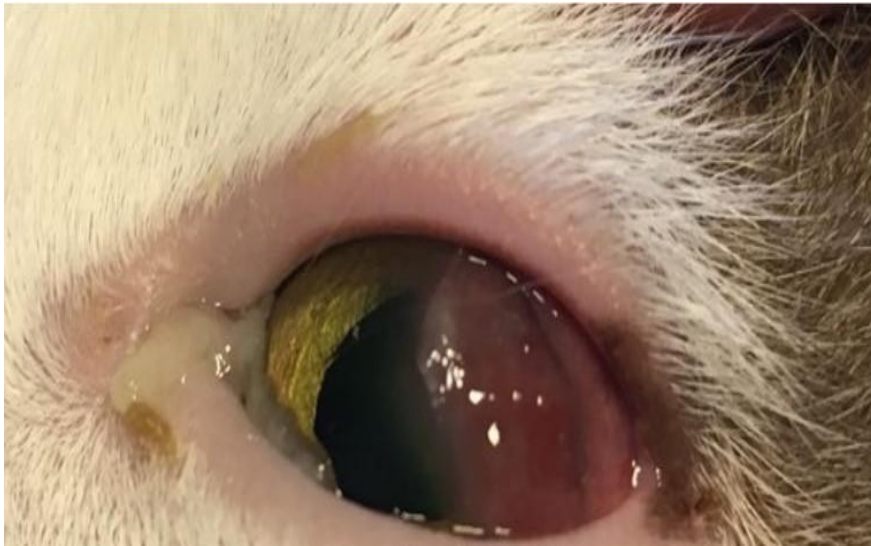

Figure 13. Superficial corneal vascularization, edema, and/or plaque-free fibrosis in a 1-year-old cat.

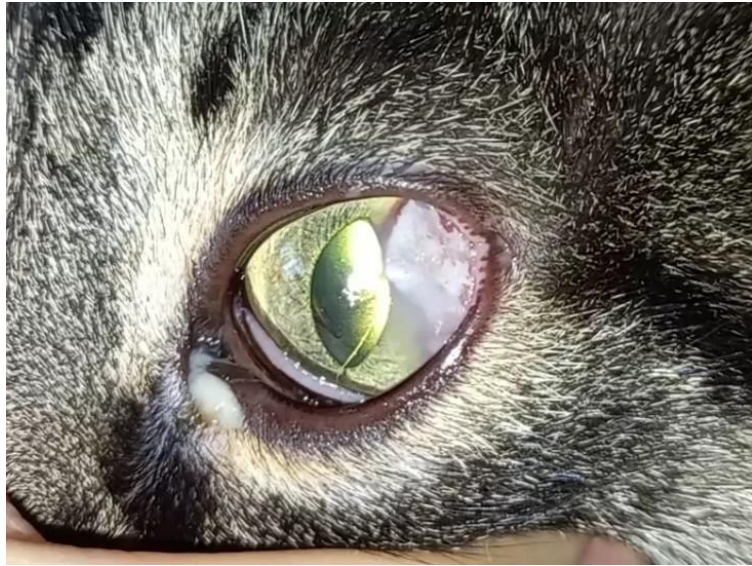

Figure 14. Proliferative (eosinophilic) keratitis. There is a thick white plaque on the lateral conjunctiva that extends over a dense neovascularized cornea.

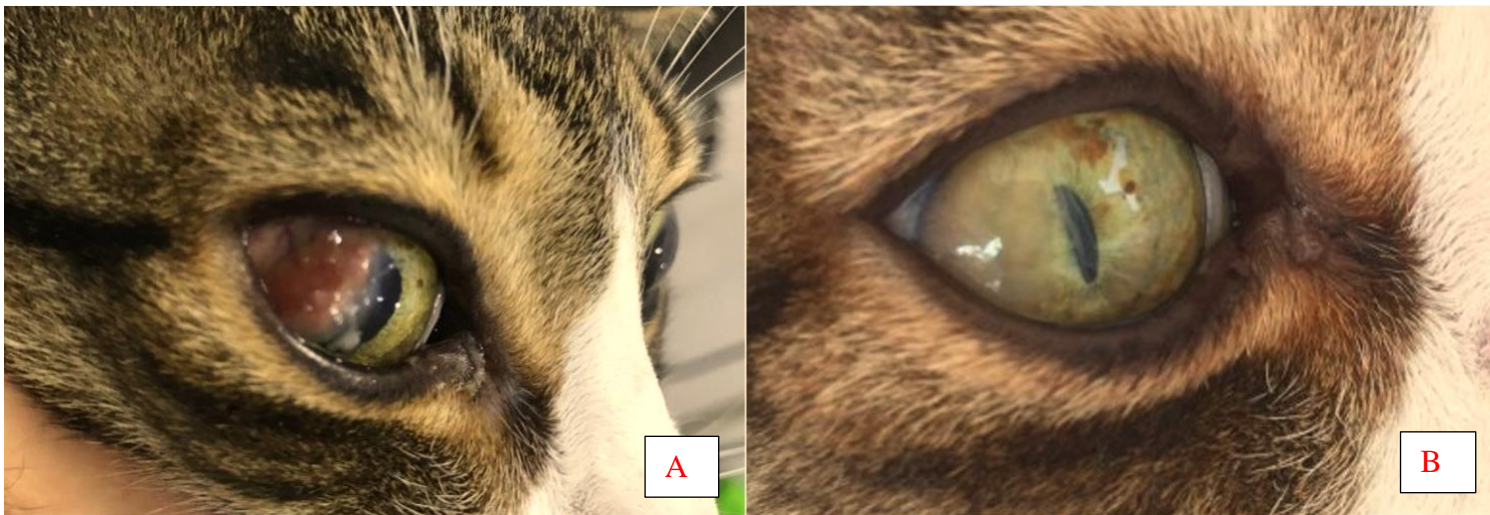


Figure 15. A. Dense proliferative keratitis of the right cornea in a 6-year-old cat. B. After 3 weeks of topical steroid therapy

DISCUSSION and CONCLUSION

Proliferative or eosinophilic keratitis has been described as a rare and progressive inflammation known to similarly affect the epithelium and stroma of the cornea and/or conjunctiva of cats and horses and characterized by a cellular infiltration of eosinophils, mast cells, neutrophils, lymphocytes, plasma cells, and sometimes histiocytes (Hodges 2005). It has been reported that lesions characteristically begin as single or multiple focal, raised pink plaques like granulation tissue in the peripheral area, progress toward superficial vascularization and stromal infiltration in the entire cornea, and have a granular or cobblestone appearance. In addition to the cornea, this condition can also invade the inner surface of the eyelids and the membrane of the bulbar conjunctiva, resulting in more widespread inflammation in the eye (Ahn et al. 2010).

In the current study, the corneal lesions were mostly located in the superotemporal quadrant of the cornea (75, 33/44), followed by the inferonasal quadrant (18.18%, 8/44) and less frequently observed in the central surface (6.81%, 3/44). Depending on the time from the emergence of the lesions to presentation, there were fluffy pink plaques like granulation tissue in the cats referred to our department at the initial stage, while in advanced stages, the cases presented with white or chalky plaques. These findings are consistent with the previous reports describing the formation of lesions and their position in the cornea. We also determined that the size of the lesions varied according to the chronicity, and the cats generally had more disturbing symptoms as the lesions progressed. All the cats had superficial vascularization and stromal infiltration of the cornea. Irregularly shaped, pink to white infiltrates with rough corneal plaques were present in 68.18% of the examined eyes. In two cases where the inferonasal quadrant was involved, lesions were also seen in the nictitating membrane. In five cases, the proliferative lesions started from the limbal region and progressed to the central cornea, covering a very large area of the corneal surface. Of all the cats with FEK, 22.72% also had corneal ulcers in and around their lesions at the time of the diagnosis of the disease. The rate of corneal ulcers accompanying FEK was 22.72% in our study, which was like the findings previously reported by Dean and Meunier (33.3%), Spiess (28.63%), and Morgan et al. (24%) and higher than the rate determined by Paulsen (13%).

FEK lesions tend to be more common in young and middle-aged, sterilized males, and domestic shorthair, longhair and purebred cats (Stiles and Coster 2016). Most of the data obtained from the current study, such as the mean age at diagnosis (4.19 years) (range 3 months to 13 years), breed and sex of the cats affected, and the eye affected by the lesion are

consistent with previously published results. The affected cats varied in age at the first presentation, but FEK was usually seen in young to middle-aged adult cats. In previous studies and our study, domestic cats were identified as the most affected breeds (82.85%). However, in the current study, there were also three pure cat breeds representing Persian (5.71%), Siamese (5.71%) and British Shorthair (5.71%) cats. FEK lesions are usually unilateral, but if left untreated or treated inappropriately, the disease can affect both eyes (Ahn et al. 2010). Generally, first, one eye is affected, and a few months later, the second eye begins to show symptoms. Bilateral lesions usually occur when the treatment of the first lesion is ineffective (Ahn et al. 2010). According to a retrospective study, approximately 80% of the FEK cases were unilateral (Ahn et al. 2010). In a study indicating no age, breed, or sex predisposition to the disease, it was reported that the lesions occurred unilaterally in 66% of the cases (Chisholm 1989). In our study, most of the cases, 74.28% (n = 26), presented with a unilateral lesion, while the remaining nine cases had bilateral lesions, and the left eyes were more frequently affected than the right eye. According to Dean and Meunier, the right and left eyes were equally affected. In two cases, one eye was affected first, while the second eye showed symptoms months later. Bilateral involvement was defined as disease progression. While the sex ratio of the male and female cats affected by these lesions was close to 1 according to the studies of Nasisse et al. and Dean and Meunier, it was observed that males (23/35) were predominantly affected by these lesions at a rate of 65.71%. Similarly, previous studies by Spiess, Morgan et al. and Paulsen et al. reported that the lesions affected male cats more.

The probable diagnosis of FEK is often based on the characteristic appearance of lesions on an ophthalmic examination, and this disease is suspected when there is a history of failure to respond to antibiotic therapy (Chisholm 1989, Hodges 2005). Under normal conditions, eosinophils and mast cells are not seen in healthy cat corneas. The clinical appearance and corneal infiltration of one of these two inflammatory cells in the corneal cytology is pathognomonic for proliferative FEK. Although this disease may have a classical, almost pathognomonic appearance in cats, the definitive diagnosis is made based on the cytological examination of corneal scrapings or light microscopy of corneal biopsies (Hodges 2005, Ahn et al. 2010). Diagnostic samples are obtained using the Microbrush® applicator, cotton swabs, Kimura spatula, or the blunt (handle) tip of a scalpel blade (Spiess et al. 2009). In the current study, a history of unresponsiveness to long-term antibiotic therapy and ophthalmological examination findings of some cases created suspicion of the disease, but the definitive diagnosis was confirmed based on cytological findings, as described in previous publications (Spiess et al. 2009, Stiles and Coster 2016, Sancak et al. 2011).

A blunt-tipped corneal knife or cotton swabs were used in the cytology of the affected areas. The cytological appearance was like what was previously described (Spiess et al. 2009, Dean and Meunier 2013, Stiles and Coster 2016). The results showed the presence of mainly eosinophils (86.36%), neutrophils (63.63%) and mast cells (72.85%), while lymphocytes and plasma cells were seen less frequently.

The etiology of eosinophilic keratitis has not yet been fully determined, but the literature contains various assumptions, including parasite invasion, allergic components, and immune reactions (Stiles and Coster 2016). Some studies suggest that eosinophilic keratitis emerges as an immune response to an antigenic stimulus. Considering the cellular profile, it is suggested that the eosinophilic response can be explained by a type I or type IV hypersensitivity reaction. In a previous study, the disease was considered to develop idiopathically (Hodges 2005). However, none of these ideas have been confirmed to date. In another study, eosinophilic keratitis was associated with FHV-1 diagnosed based on a PCR analysis (Stiles and Coster 2016). In the current study, hypotheses based on systemic clinical findings and anamnesis were made in some of the cases in which the disease etiology could not be precisely determined due to the necessary tests not being performed for reasons such as the financial constraints of the guardians or due to the results of the examination not being significant. We determined that 20% of the cases were positive for FHV-1. However, as reported in previous studies (Chisholm 1989, Hodges 2005), we consider that FHV-1 positivity in the samples taken from the eyes of cats does not necessarily indicate that the two diseases have a cause-and-effect relationship.

The most common form of treatment for FEK has been identified as medical therapy with anti-inflammatory drugs. Due to its chronic character, the disease can only be controlled but not cured. Long-term or even life-long treatment at a low and effective dose is required to control the disease. Topical steroids are the first choice for treatment due to their high efficacy and minimal side effects, and they are crucial in the success of treatment (Raczynska et al. 2003). However, their use in FEK is not completely risk-free. In the presence of FHV-1, which plays an important pathogenic role in the etiology of the disease, long-term immunosuppressive therapy can theoretically facilitate the recurrence of an FHV-1 infection (Chisholm 1989, Hodges 2005). Nevertheless, the topical application of antiviral drugs provides an advantage for treating suspected cases of herpetic keratitis. Other recommended treatments for the disease include systemic corticosteroids and megestrol acetate (Ovaban; Schering-Plough Animal Health, Pointe Claire, Quebec) and recently applied topical formulations of cyclosporine, tacrolimus (Aydın and Aktaş 2021) and megestrol acetate (Stiles

and Coster 2016). However, oral corticosteroids should not be used as first-line drugs due to the high dose required for immunosuppression and possible side effects. Megestrol acetate has been suggested to be beneficial in cats with a history of recurrent FEK, but caution should be exercised since it causes adrenocortical suppression, polyphagia, behavioral changes, diabetes mellitus, mammary hyperplasia, and neoplasia, and it is not licensed for use in cats and has a half-life of eight days. Depending on the clinical manifestation, other methods can be used in addition to local and systemic drug use (Chisholm 1989, Hodges 2005). In large-scale granulomas, a superficial keratectomy can usually accelerate the healing process (Hodges 2005). In our study, the size of the lesions, their clinical appearance, and the symptoms of the cases widely differed, the etiology of the disease could not be precisely determined, and the viral etiology was dubious; therefore, topical corticosteroids were simultaneously applied with antivirals. After treatment, no ocular clinical signs related to an FHV-1 infection were observed in any of the cases with FHV-1 positivity at the time of presentation. In most of our cases, the topical steroid application resulted in the disappearance of white plaques and neovascularization by the second to fourth day of treatment, and the disease was taken under control within a few weeks. However, a few cats required intermittent drugs to keep the disease under control. Morgan reported that the recurrence rate of FEK was over 64%. The author noted that recurrence developed at six months after treatment, and clinical symptoms disappeared after 20 days of the topical application of 1% prednisolone. In another study conducted with 65 cats, Morgan et al. reported a recurrence rate of 64%, and recurrence was observed in all treatment modalities (Hodges 2005). In our study, the recurrence rate in controlling FEK with topical steroids was determined as 11.76%. Recurrence developed after 6 months, and the clinical complaints disappeared after two to three weeks of topical dexamethasone. In conclusion, as in previous studies, it was determined that feline eosinophilic keratitis was mostly seen in unilateral domestic short/longhair cats. The clinical appearance of the lesions was pathognomonic; however, it was easily performed by cytological examination at 40x magnification to confirm the diagnosis. Also, topical steroid and antiviral ophthalmic solutions were determined to be effective treatments in the control of FEK in all cases presenting to our referral center.

Çıkar Çatışması: Yazarlar bu yazı için gerçek, potansiyel veya algılanan çıkar çatışması olmadığını beyan etmişlerdir.

Etik İzin: Bu çalışma kliniğimize rutin göz hastalıkları şikâyeti ile sevk edilen ve medikal tedavi uygulanan klinik çalışmadır. Her hastaya reçete edilen

medikal tedavi için hasta sahiplerinden tedaviyi kabul ettiklerini gösteren imzalı onam belgesi alınmıştır.

Finansal destek: Finansal destek alınmamıştır.

Teşekkür: Bu çalışmada sitolojik inceleme sırasında desteklerini veren Veteriner Hekim Erhan GÜLÇİK'e teşekkürlerimi sunarım.

REFERENCES

- Ahn JT, Jeong MB, Kim SE, Park YW, Kim TH, Ahn JS, Seo KM.** A Case of Feline Proliferative Eosinophilic Keratitis Treated by Topical Cyclosporine and Corticosteroids. *Journal of Veterinary Clinics.* 2010; 27(6): 751-754.
- Aydın Ö, Aktaş MS.** Kedi ve Köpeklerde Kullanılan Bazı İmmünsupresif İlaçlar ve Kullanım Amaçları. *Bozok Veterinary Sciences.* 2021; 2(2): 101-107.
- Chisholm WH.** Feline eosinophilic keratitis. *The Canadian Veterinary Journal.* 1989; 30(5): 438.
- Dean E, Meunier V.** Feline eosinophilic keratoconjunctivitis: a retrospective study of 45 cases (56 eyes). *Journal of feline medicine and surgery.* 2013; 15(8): 661-666.
- Edwards S, Clode AB, Gilger BC.** Equine eosinophilic keratitis in horses: 28 cases (2003–2013). *Clinical case reports* 2015; 3(12): 1000.
- Hodges A.** Eosinophilic keratitis and keratoconjunctivitis in a 7-year-old domestic shorthaired cat. *The Canadian Veterinary Journal.* 2005; 46(11): 1034.
- Lucyshyn DR, Good KL, Knickelbein KE, Chang MW, Strøm AR, Hollingsworth SR, Maggs DJ.** Subcutaneous administration of triamcinolone as part of the management of feline eosinophilic keratoconjunctivitis. *Journal of Feline Medicine and Surgery.* 2021; 23(6): 575-583.
- Morgan RV.** Feline Eosinophilic Keratitis. <http://www.saintfrancis.org/wp-content/uploads>
- Morgan RV, Abrams KL, Kern TJ.** Feline eosinophilic keratitis: A retrospective study of 54 cases. *Vet Comp Ophthalmol.* 1996; 6: 131-134.
- Nasise MP, Glover TL, Moore CP.** Detection of feline herpesvirus 1 DNA in corneas of cats with eosinophilic keratitis or corneal sequestration. *Am J Vet Res.* 1998; 59: 856–858
- Paulsen ME, Lavach JD, Severin GA, Eichenbaum JD.** Feline eosinophilic keratitis: A review of 15 clinical cases. *J Am Anim Hosp Assoc.* 1987; 23: 63-69
- Raczyńska K, Iwaszkiewicz-Bilikiewicz B, Stozkowska W, Sadlak-Nowicka J.** Clinical evaluation of provitamin B5 drops and gel for postoperative treatment of corneal and conjunctival injuries. *Klinika oczna.* 2003; 105(3-4): 175-178.
- Romanek AK, Sebbag L.** Case Report: Clinical Remission in a Cat with Severe Bilateral Eosinophilic Keratitis Receiving Combined Immunosuppressive Therapy (Triamcinolone Acetonide and Tacrolimus). *Frontiers in Veterinary Science.* 2021; 8: 401
- Sancak İG, Eser Özgencil F, Arda Sancak A.** Kedide eozinofilik keratitis. *Veteriner Hekimler Derneği Dergisi.* 2011; 82(2): 3-6.
- Spieß AK, Sapienza JS, Mayordomo A.** Treatment of proliferative feline eosinophilic keratitis with topical 1.5% cyclosporine: 35 cases. *Veterinary ophthalmology.* 2009; 12(2): 132-137.
- Stiles J, Coster M.** Use of an ophthalmic formulation of megestrol acetate for the treatment of eosinophilic keratitis in cats. *Veterinary Ophthalmology.* 2016; 19: 86–90. doi:10.1111/vop.12371