

## Mycosis Fungoides and Pregnancy: A Case Report

### *Mikozis Fungoides ve Gebelik: Vaka Sunumu*

Mustafa ÖZTÜRK<sup>1</sup>, Murat DEDE<sup>1</sup>, Hakan ÇOKSÜER<sup>1</sup>, Uğur KESKİN<sup>1</sup>, Cihangir Mutlu ERKAN<sup>1</sup>, İskender BAŞER<sup>1</sup>, Ahmet AKAR<sup>2</sup>

<sup>1</sup> *Gülhane Askeri Tıp Akademisi, Kadın Hastalıkları ve Doğum AD, Etlik, Ankara*

<sup>2</sup> *Gülhane Askeri Tıp Akademisi, Deri ve Zührevi Hastalıkları AD, Etlik, Ankara*

#### ABSTRACT

**Aim:** The aim of this case report was to examine the effect of mycosis fungoides on pregnancy, the pattern of mycosis fungoides during pregnancy and the literature review.

**Case:** The patient was 30 and gravida 1 and parity 1. She was 7 weeks pregnant when she applied to our clinic and her treatment was interfered because of the pregnancy. Psoralen and ultraviolet-A light (PUVA) therapy was applied to the patient.

**Conclusion:** The effect of MF on pregnancy is not known well due to the limited number of cases and there were not important side effects of the MF observed in our case. However, more studies are needed considering the effect of MF on pregnancy and MF therapy during pregnancy.

**Key Words:** Mycosis Fungoides, pregnancy

#### ÖZET

**Amaç:** Bu vaka sunumunda mycosis fungoides'in (MF) gebelik üzerine etkisini ve gebelikte mycosis fungoides paternini ve literatürün gözden geçirilmesi amaçlanmıştır.

**Vaka:** Hasta 30 yaşında, gravidası 1, paritesi 1 idi. Kliniğimize 7 haftalık gebelikle başvurdu ve tedavisine gebelik nedeniyle ara verildi. Hastaya Psoralen ve ultraviyole -A light (PUVA) tedavisi uygulandı.

**Sonuç:** Gebeliğe MF'in etkisi, sınırlı vaka sayısı nedeni ile tam bilinmemektedir ve vakamızda MF'nin önemli yan etkisi gözlenmemiştir. Fakat gebelikte MF'in etkisi ve gebelik süresince MF tedavisi ile ilgili daha geniş çalışmalara ihtiyaç vardır.

**Anahtar Kelimeler:** Mikozis Fungoides, gebelik

#### INTRODUCTION

Mycosis fungoides (MF) is a type of non-Hodgkin lymphoma with skin manifestations, and it is a T-cell originated, extranodal, painless lymphoma. Cutaneous T-cell lymphoma (CTCL) is a disease of the good prognosis group (1). The incidence is quite rare, the annual number of new cases is 6/1.000.000 (2). MF is usually considered as a disease of the elderly and the peak age is 55-60 years. Male / female ratio was 2 / 1 (3). The most common clinical feature of mycosis fungoides (MF) is patched, infiltrative plaques, tumors, generalized erythroderma, poikilodermacytosis and papules (4, 5). Early stages of MF manifests different clinical forms with bullous,

hypopigmented, verrucous, pustular, granulomatous, hyperkeratotic lesions and purpuric capillaritis (6-7).

The clinically significant symptom of MF can not be noticed by the patient or the physician during the early phases. Eczema lesions can occur in the early phases and the diagnosis of MF can be recognized with multiple repeated biopsies in this period (8). The nonspecific scaly skin lesions may appear from several months to several years (average six years) and this period is characterized by inflammation and itchiness (9). Pre-mycotic stage lesions may give respond to topical corticosteroids or spontaneous regression may be seen. Many agents have been implicated in the etiology and risk factors (9).

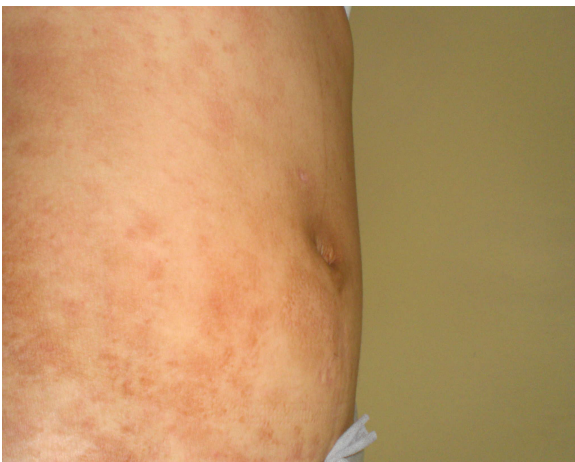In the diagnosis of MF; clinical, histopathological, molecular biological, and immunopathologic criteria are evaluated together (10, 11). Histopathologic features include prominent epidermotism, the presence of atypical lymphocytes that form groups of epidermis, large hyperchromatic nuclei in epidermis,

irregular nuclear contours, perinuclear halo within atypical cells, full lymphocytes along by the dermoepidermal junction. However, infiltrative atypia of lymphocytes in the dermal histopathological junction suggest MF.

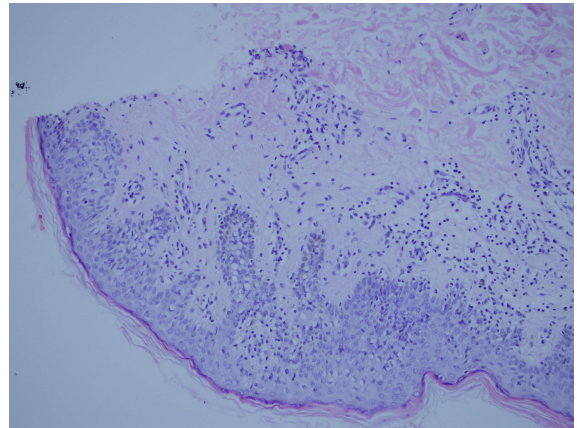
The information about the development of MF during pregnancy is quite inadequate, and the pathogenesis of MF during pregnancy has not been known clearly. There are a few case reports in the literature (12-13). Therefore, the impact of mycosis fungoides on pregnancy is unknown. The aim of this case report was to examine the effect of mycosis fungoides on pregnancy, the pattern of mycosis fungoides during pregnancy and the literature review.

### CASE REPORT

The patient was 30 years old, gravida 1, parity 1. MF was diagnosed two years ago from pregnancy (first occurred at the age of 27). The patient applied to the dermatology clinic with purpuric skin lesions and pruritus, a history of itchiness and redness of the entire body spreading from legs, in the the dermatological examination, trunk, arms, legs and feet of different sizes, some red, some brown petechiae macular lesions were found (Figure 1). Routine laboratory tests were normal. After biopsies of existing lesions, superficial perivascular lymphocytic infiltration and minimal egzocytosis were identified (Figure 2). Two months later, biopsy was repeated and the same results were obtained.



**Figure 1:** Purpuric skin lesions and pruritus



**Figure 2:** Superficial perivascular lymphocytic infiltration and minimal egzocitoz

Diagnosis of MF was based on the clinical and histopatological diagnostic criteria of the European Organization for Research and Treatment of Cancer (EORTC) (14). Mycosis fungoides was diagnosed in the early stage. Three cycles of Psoralen and ultraviolet-A light (PUVA) treatment was applied to the patient, and pregnancy was not present during the process of the treatment. She was 7 weeks pregnant when she applied to our clinic and her treatment was interfered because of the pregnancy. During periconceptional period, the pregnant received 3 cycles of PUVA. The patient hasn't been diagnosed with a chronic disease previously. The pregnant had been observed up to 39 weeks according to the routinely antenatal follow-up protocol. There were no changes in the severity and frequency of the lesions in pregnancy. No complications developed during the early and the late pregnancy period. A cesarean section was performed on the patient with a diagnosis of dysfunctional action. Baby girl was born at term with a birth weight of 3100 gr. No changes were observed in the course of the disease and lesions in the postpartum period.

### DISCUSSION

During pregnancy, many systemic, metabolic, endocrine and vascular changes occur. As a result of these changes various cutaneous changes may occur. These changes may be physiological or pathological. Generally, pregnancy can cause enlargement and the increase of cutaneous tumors (14). Because of the low incidence, more frequent occurrence in males and often seen in the elderly, there are quite limited

## Mycosis Fungoides and Pregnancy

*Mikozis Fungoides ve Gebelik*

number of literature data on the effect of pregnancy on MF (15).

MF may manifest as different lesions, pigmented purpuric eruptions (PPD) is likely to be seen in the beginning or these findings may also occur during the course of the disease. These eruptions can imitate the PPD in both clinical and histopathologic diagnosis of MF, but MF can be diagnosed as a result of serial biopsies.

There is large, hyperchromatic, irregular nuclei and narrow cytoplasm of atypical lymphocytes seen in multiple places in dermal infiltration. The histopathologic features of repeated biopsies at two months distance diagnosed MF. MF is rare in pregnancy. In a pregnant women with MF followed by Castelo Branco et al., no exacerbation of existing lesions was observed (16). 3 cases of pregnancy with MF was followed by Echols et al. There was only 1 case in which an increase in the last trimester skin lesions have been identified and treated with topical steroids and PUVA treatment. A week later, the recurrence of the disease has improved dramatically with interferon  $\alpha$  (17). In another study, nine pregnant women were evaluated with MF, the exacerbation of MF and adverse effects were not observed during pregnancy (18). In our case, exacerbation was not observed in antenatal follow-up of pregnancy. We didn't give any treatments because of MF during pregnancy.

In the literature review, we found retrospectively studied nine disease case reports, only 2 of them were early stage 1A (pack / plaque) . First ages that the eruptions were seen in patients were 26 and 10. The diagnosis age was 26, however the gestational age was 29. The patient had been treated with PUVA and was in complete remission before pregnancy. Mild relapse occurred during conception and partial remission was provided with using only topical steroids. Neonatal care was normally. The other case lesions occurred at the age of 10, however the diagnosis age was 32. The gestational age was advanced in local EB-treated patients before pregnancy. Neonatal results were normally observed.

The incidence of this disease during pregnancy is very low (0.3/100000). Vanderheid et al., localized long-standing eczematous eruptions in women during pregnancy. Monitored exacerbation of lesions and

neonatal outcomes were normally observed. In literature, there are only two cases of stage 1A during pregnancy. In this stage, no patients treated with PUVA, however PUVA + TC treatment was started while the patient was unaware of her pregnancy and cut off with her own desire.

Mutagenic and teratogenic effect of PUVA treatment on pregnancy has been proposed in different studies, even if there is any evidence that is proven. (19)

In our case, there were not any teratogenic effects observed on the results during the early and late pregnancy. The other 3 literatures and our case report did not observe any effects either. However, the FDA's category of PUVA was C. Methoxypsoralen has very low blood level and fetal exposure and should be reproduced when the alternative choice of PUVA treatment.

The main discussion of the literature is the impact of MF on the pregnancy. T helper 1 (Th1) profile changes to T helper 2 (Th2) profile during pregnancy, and this profile of T helpers may cause progression of the MF during pregnancy. Because Th2 mediated diseases such as atopic dermatitis tend to worsen during pregnancy.

As a result, the effect of MF on pregnancy is not known well due to the limited number of cases and there were not important side effects of the MF observed in our case. However, more studies are needed considering the effect of MF on pregnancy and MF therapy during pregnancy.

## REFERENCES

1. Martinez W, Pozo J, Vazquez J: Cutaneous T-cell lymphoma presenting as disseminated, pigmented, purpura like eruption. *Int J Dermatol.* 2001; 40: 140-144.
2. Criscione, VD, Weinstock, MA. Incidence of cutaneous T-cell lymphoma in the United States, 1973-2002. *Arch Dermatol.* 2007; 143:854-856.
3. Bradford, PT, Devesa, SS, Anderson, WF, Toro, JR. Cutaneous lymphoma incidence patterns in the United States: a population-based study of 3884 cases. *Blood.* 2009; 113:5064-5067.

- 4.Hoppe, RT, Wood, GS, Abel, EA. Mycosis fungoides and the Sezary syndrome: pathology, staging, and treatment. *Curr Probl Cancer*. 1990; 14:293-296.
- 5.Morales, MM, Olsen, J, Johansen, P, et al. Viral infection, atopy and mycosis fungoides: a European multicentre case-control study. *Eur J Cancer*. 2003; 39:511-515.
- 6.Barnhill RL, Braverman IM: Progression of pigmented purpura-like eruptions to mycosis fungoides: Report of three cases. *J Am Acad Dermatol*. 1988; 19: 25-31.
- 7.Camisa C, Aulisio A: Pustular mycosis fungoides. *Cutis*. 1994; 54: 202-207.
- 8.Dalton JA, Yag-Howard C, Messina JL, Glass LF. Cutaneous T-cell lymphoma. *Int J Dermatol*. 1997; 36: 801-809.
- 9.Latkowski JA, Heald P. Cutaneous T Cell Lymphomas. In: Freedberg IM, Eisen AZ, Wolff K, (eds). *Fitzpatrick's Dermatology in General Medicine*, Vol 2, 6th ed. New York: Mc Graw Hill 2003; 52:1537-1558.
- 10.Pimpinelli, N, Olsen, EA, Santucci, M, et al. Defining early mycosis fungoides. *J Am Acad Dermatol*. 2005; 53:1053-1058.
- 11.Olsen, E, Vonderheid, E, Pimpinelli, N, et al. Revisions to the staging and classification of mycosis fungoides and Sezary syndrome: a proposal of the International Society for Cutaneous Lymphomas (ISCL) and the cutaneous lymphoma task force of the European Organization of Research and Treatment of Cancer (EORTC). *Blood*. 2007; 110:1713-1718.
- 12.Vonderheid EC, Dellatorre DL, Van Scott EJ. Prolonged remission of tumor-stage mycosis fungoides by topical immunotherapy. *Arch Dermatol*. 1981; 117: 586–589.
- 13.Amitay-Layish I, David M, Kafri B, Barzilai A, Feinmesser M, Hodak E. Early-stage mycosis fungoides, parapsoriasis en plaque, and pregnancy. *Int J Dermatol*. 2007;46:160-165.
- 14.Willemze R, Jaffe ES, Burg G, et al. WHO-EORTC classification for cutaneous lymphomas. *Blood*. 2005; 105 : 3768–3785.
- 15.Kroumpouzou G, Cohen LM. Dermatoses of pregnancy. *J Am Acad Dermatol*. 2001; 45 : 1–19.
- 16.Castelo-Branco C,Torne A,Cararac V et al. Mycosis fungoides and pregnancy *Oncol Rep*. 2001;8:197-199
- 17.Echols KT,Gilles JM ,Diro M Mycosis fungoides in pregnancy: remission after treatment with alpha – interferon in case refractory to conventional therapy : a case report.*J.Maternal Fetal Med*. 2001;10:68-70
- 18.Amtay-Layish I,David M,Kafri B et al. Early stage mycosis fungoides, parapsoriasis en plaque , and pregnancy *Int J. Dermatol*. 2007;46:160-165
- 19.Gunnerskag JG, *Arch dermatologist*. 1993;129:320-323.

